

Tarsal coalition



UNIFESP – ESCOLA PAULISTA DE MEDICINA
SÃO PAULO - BRASIL

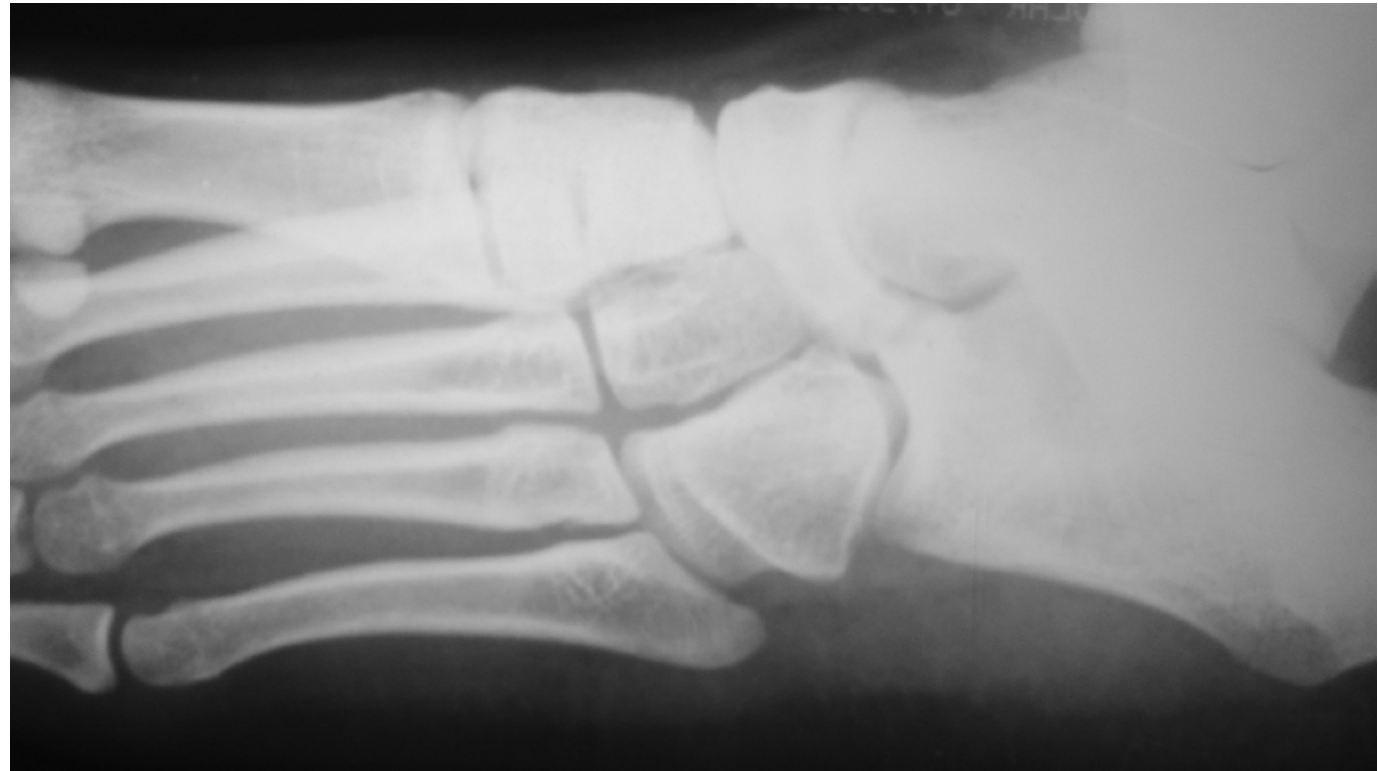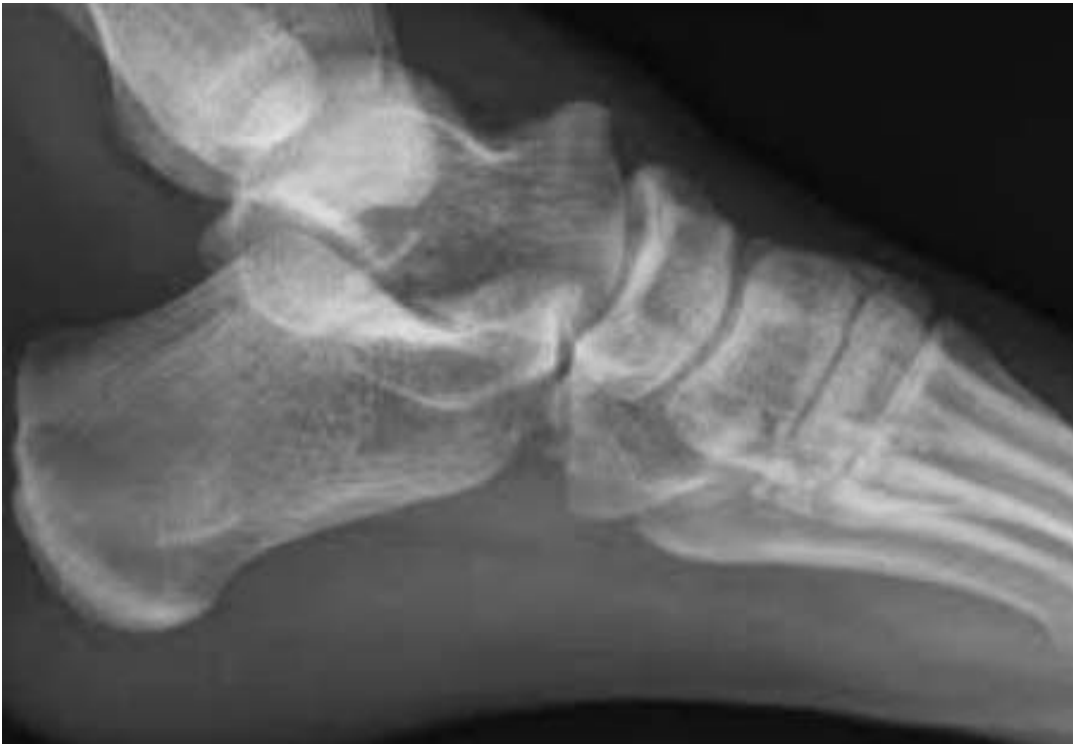Alexandre F. de Lourenço

Tarsal coalition

- Not so common: single pediatric orthopedic surgeon will not treat lots of cases
- Common enough: all pediatric orthopedic surgeons will treat at least some cases during his/her career.

Most frequent coalitions

- Talocalcaneal (middle facet)
- Calcaneonavicular



Multiple unilateral tarsal coalitions in a non syndromic patient

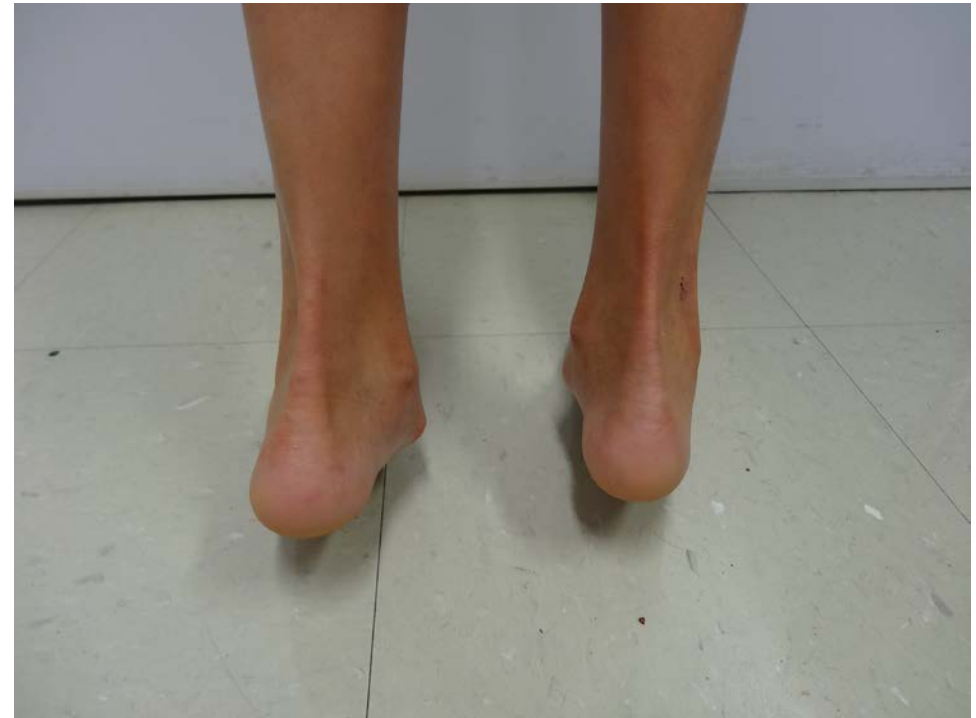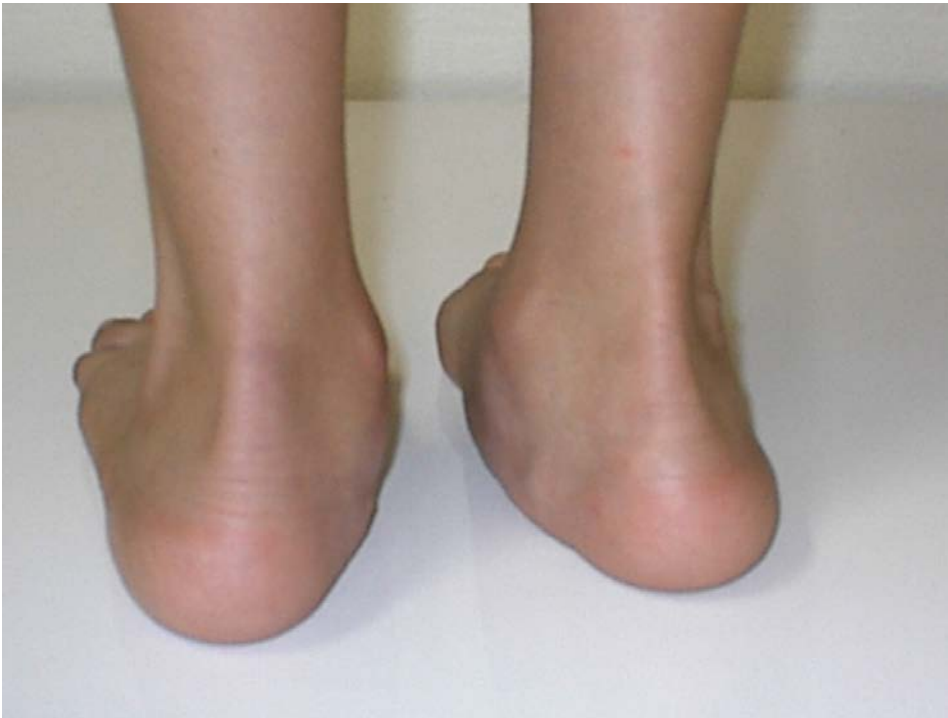The coexistence of calcaneonavicular and talocalcaneal coalitions in the same foot in nonsyndromic patients has been rare

Richer et al, *Clin Imaging* 40(@): 247-50, 2016

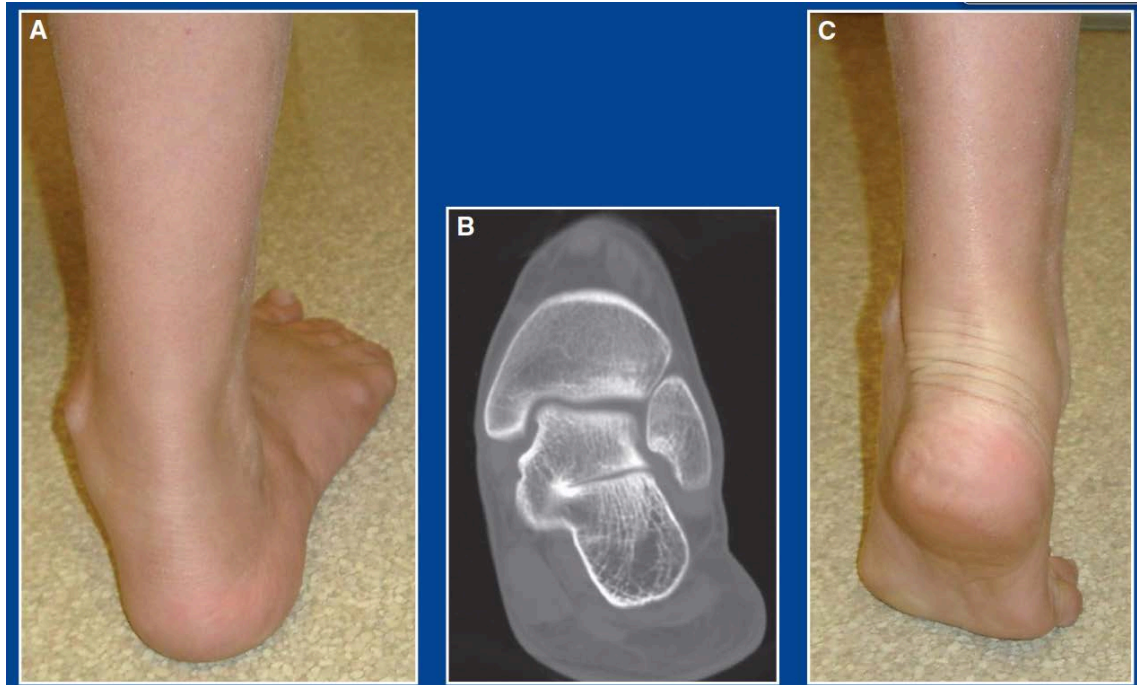
Coalitions

Clinically symptomatic

- pain and/or decreased ROM



Beware of compensatory motion at Chopart joint

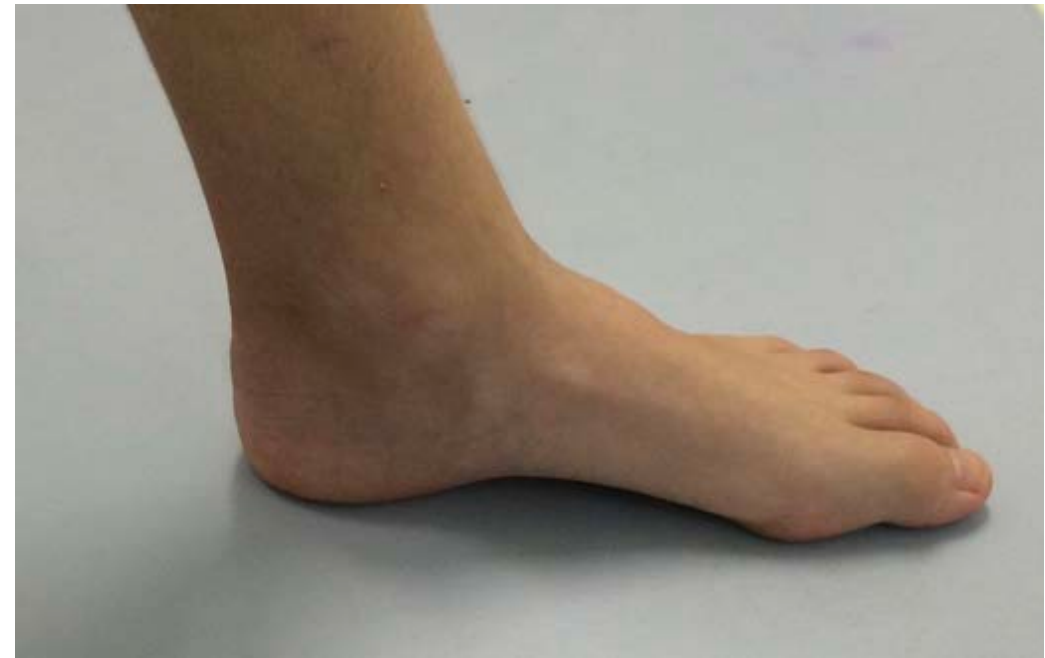
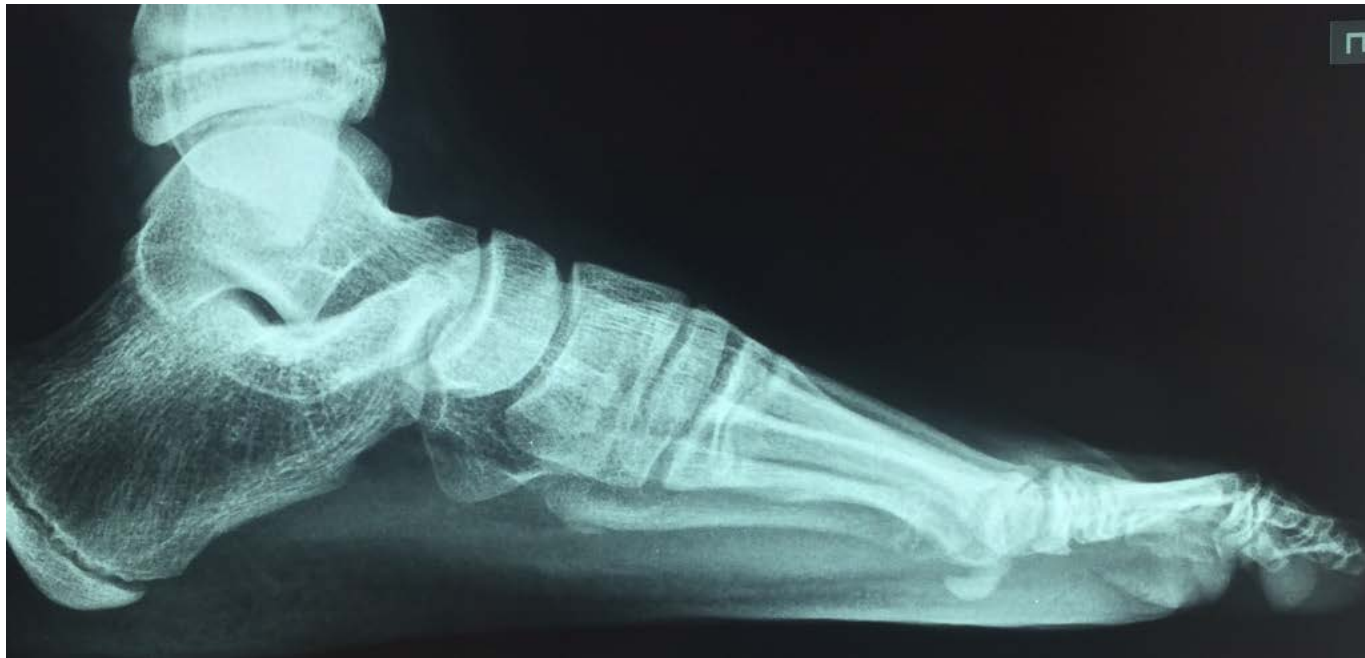
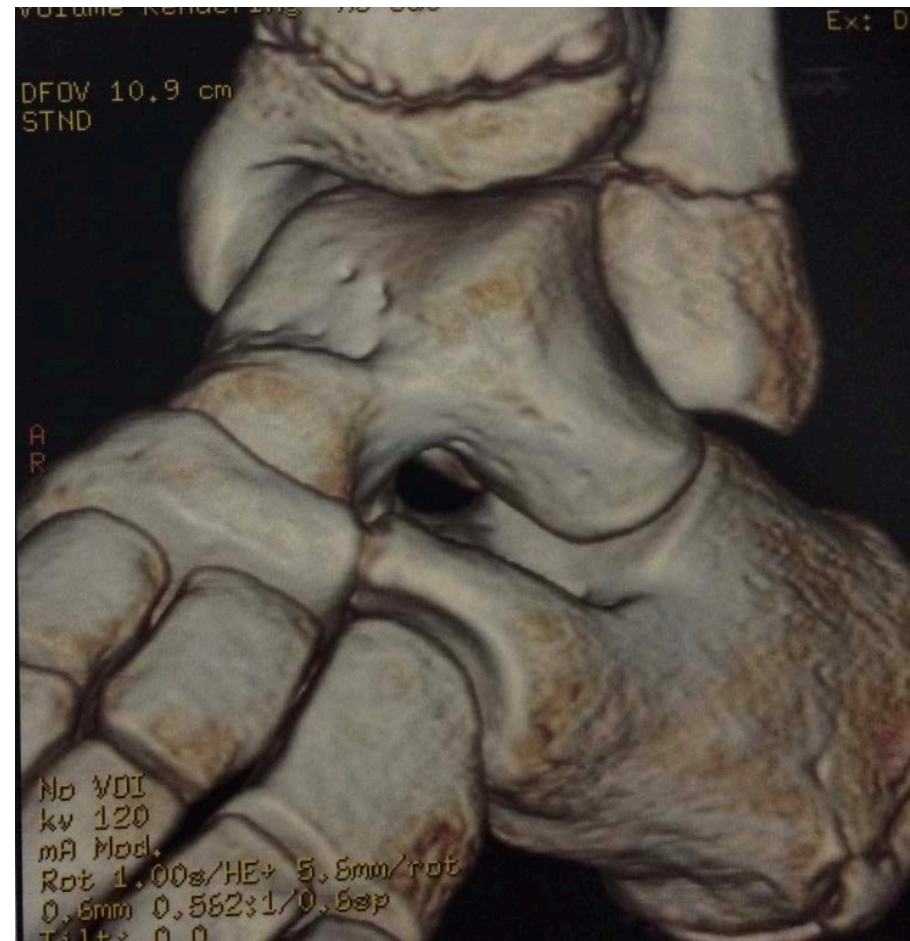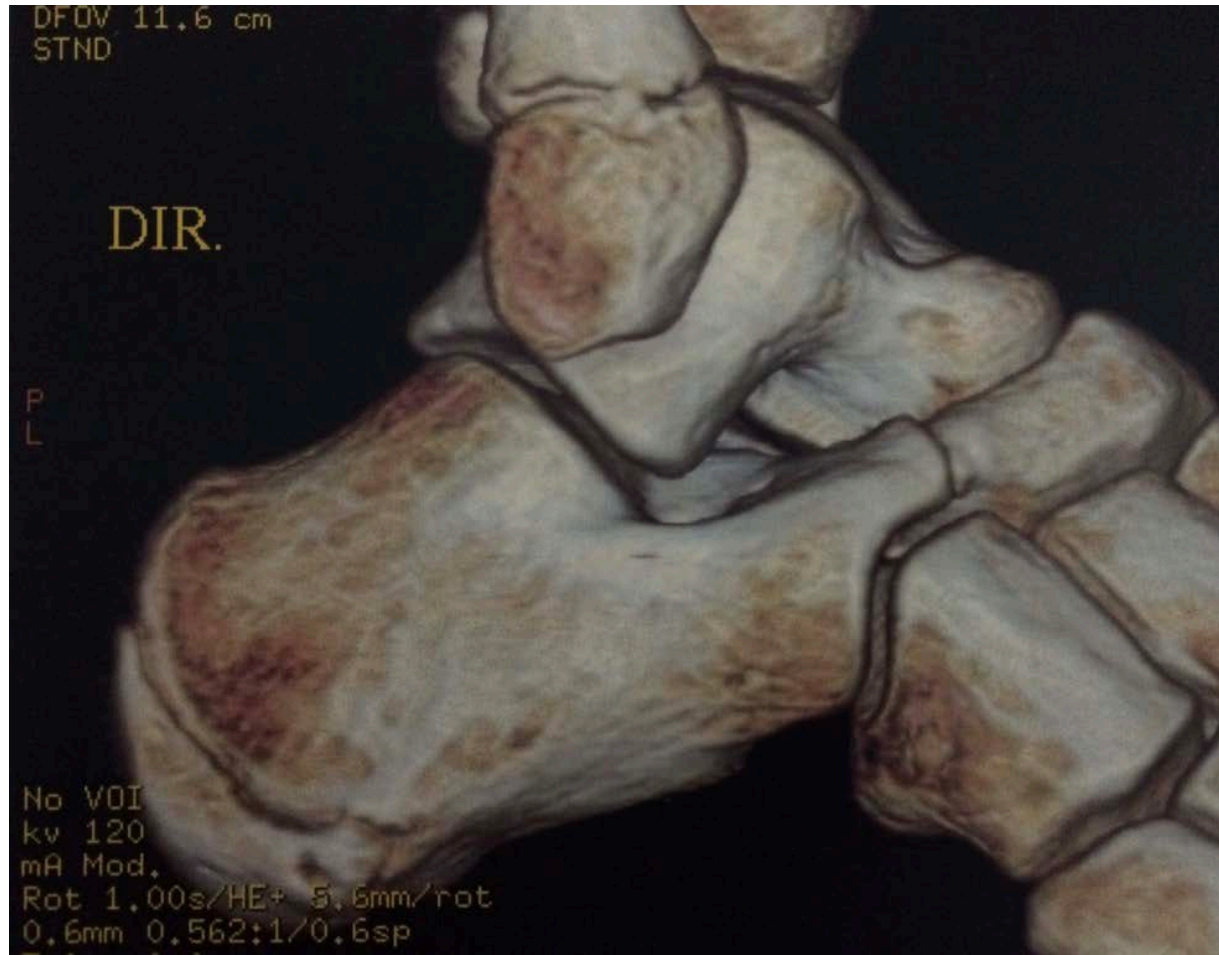
VINCENT S. MOSCA

**Principles and
Management of
Pediatric Foot and
Ankle Deformities
and Malformations**

Mosca, 2015

Coalition with cavus foot



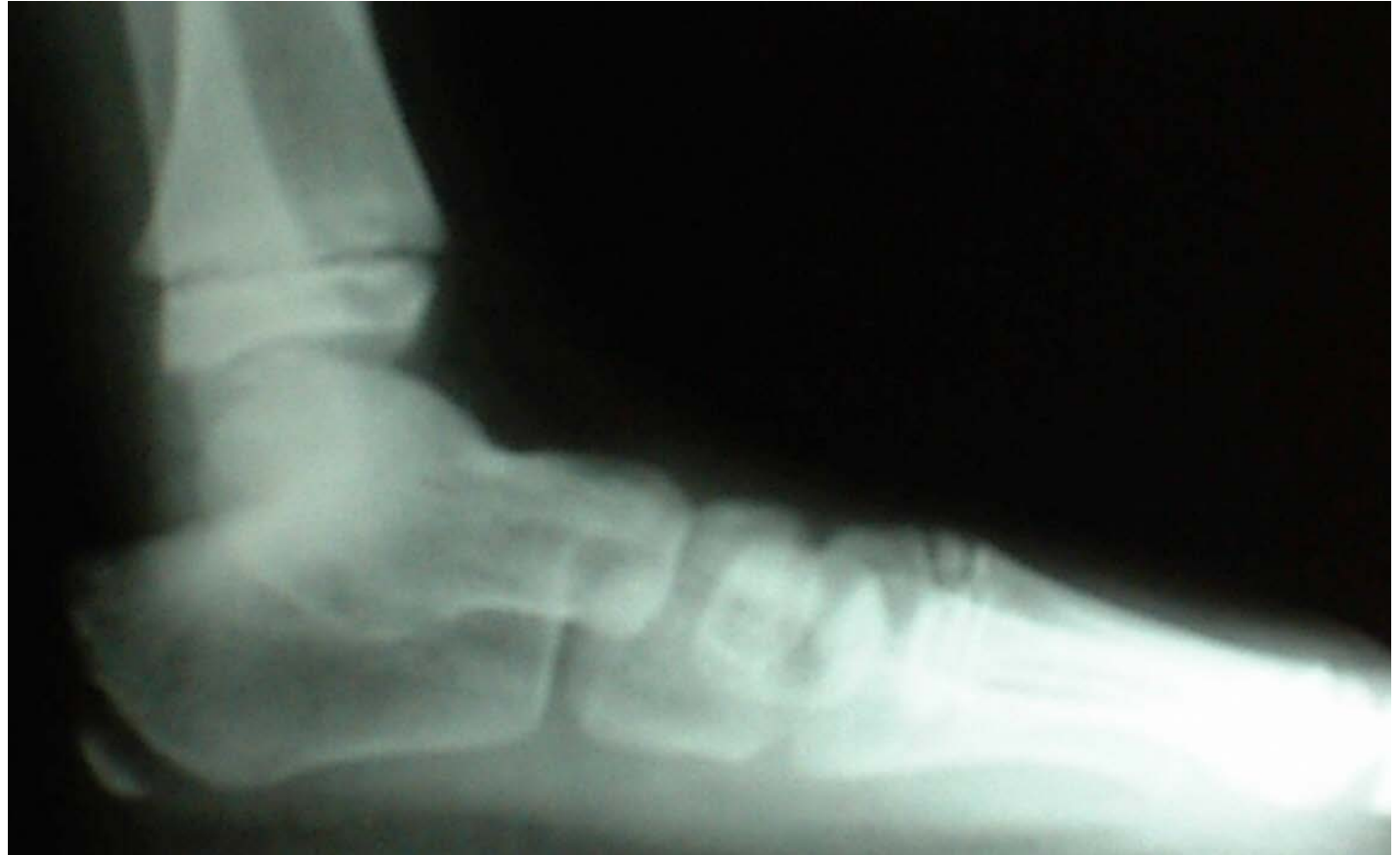

Coalitions

Asymptomatic

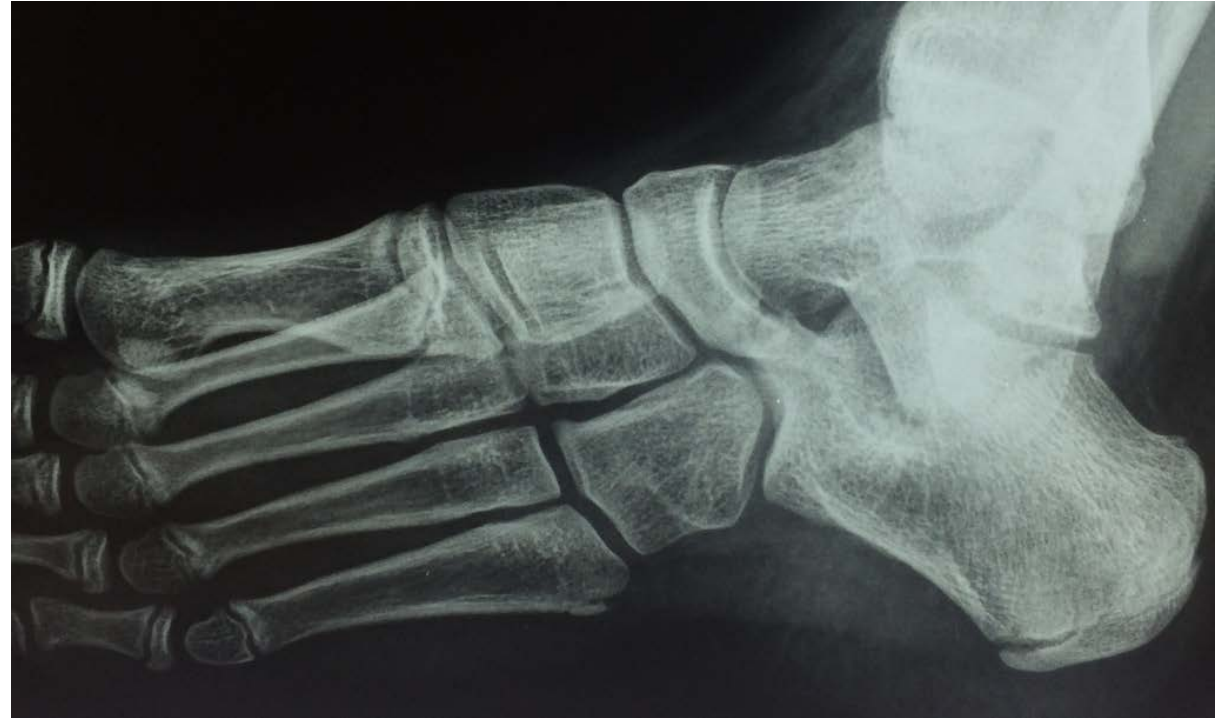TN coalition

Occasional finding

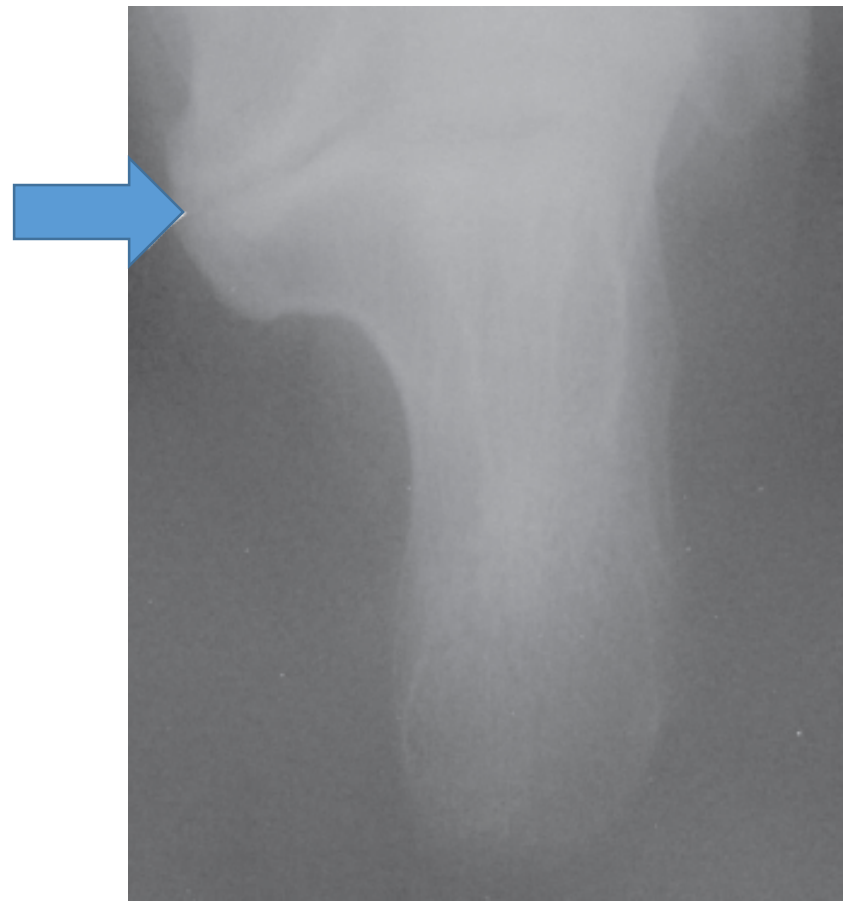
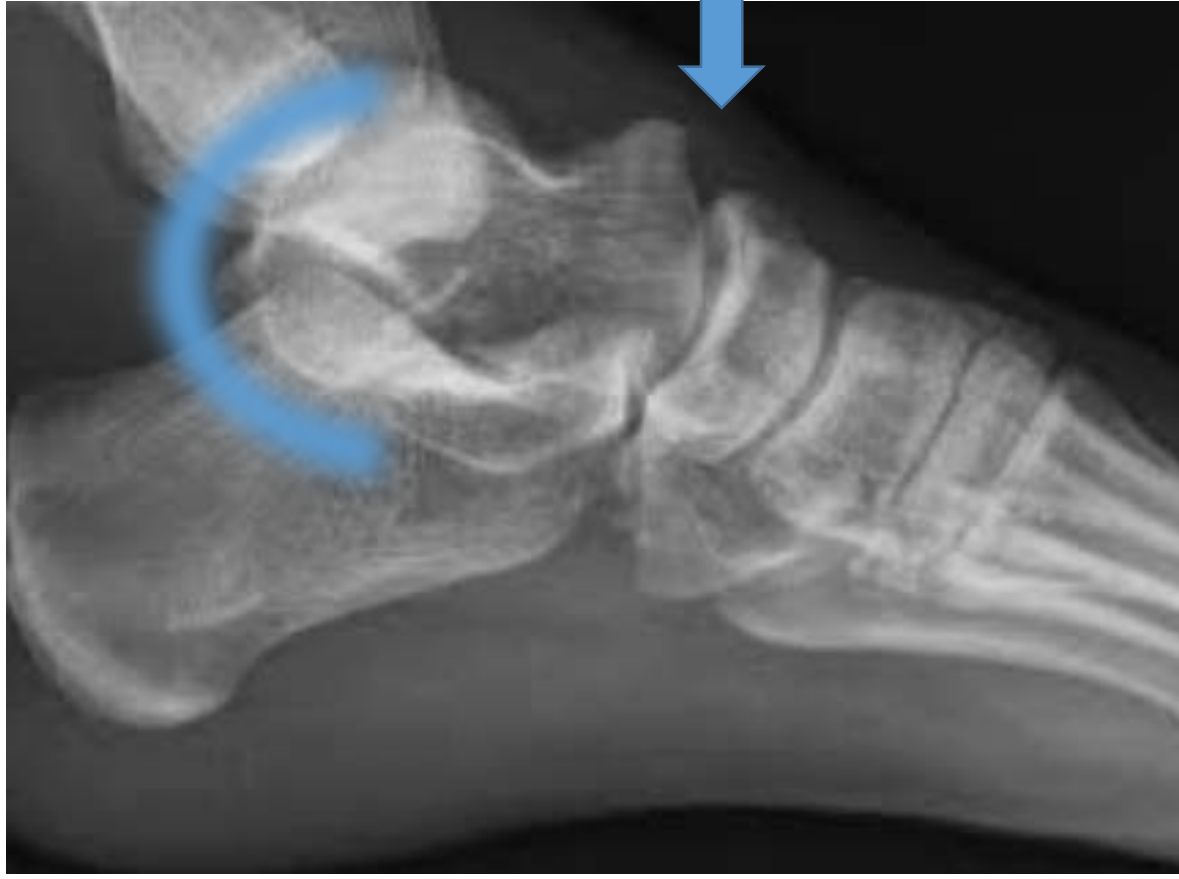
Radiographic study

- AP/Lateral
- Oblique
- Harris view

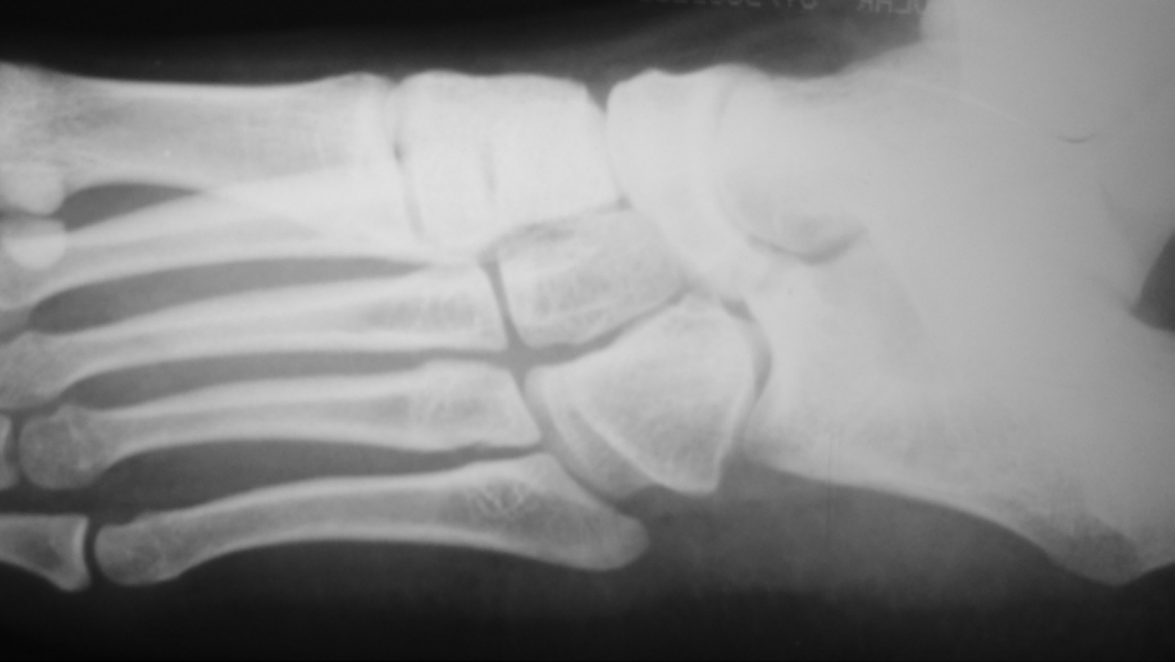
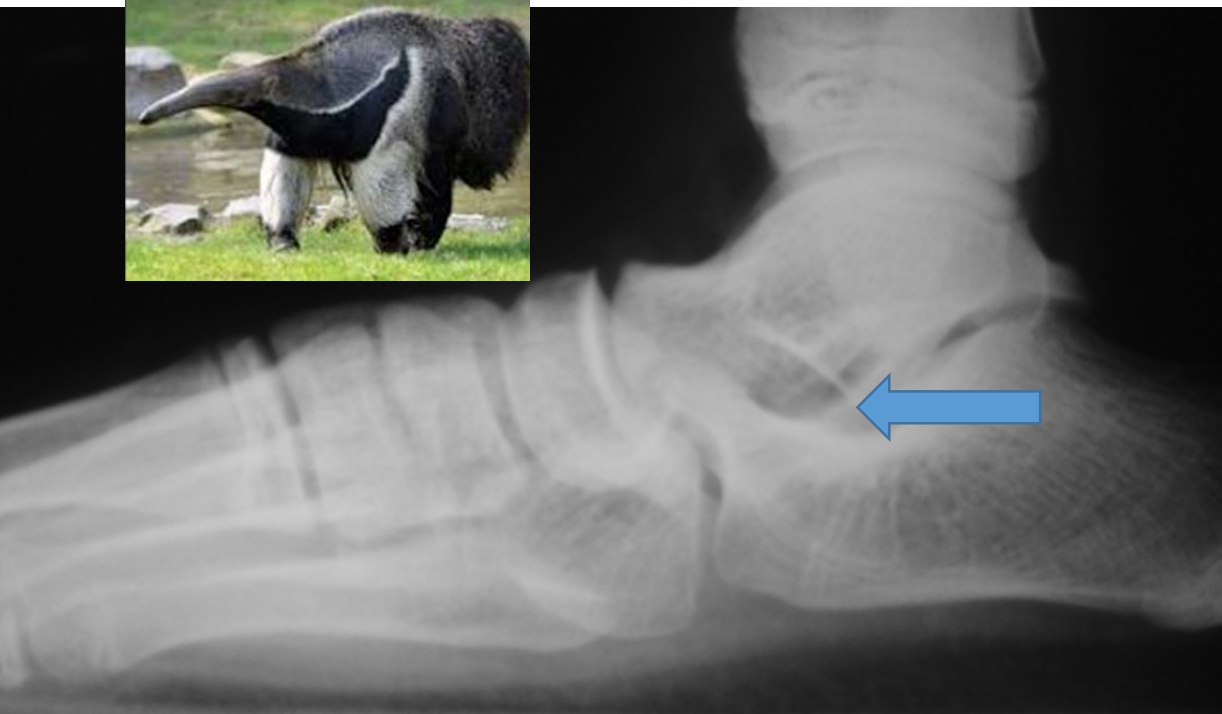
TC Coalition: radiographic signs



C sign of Lateur and TN spur

Lateral and oblique view: usually enough for CN coalition



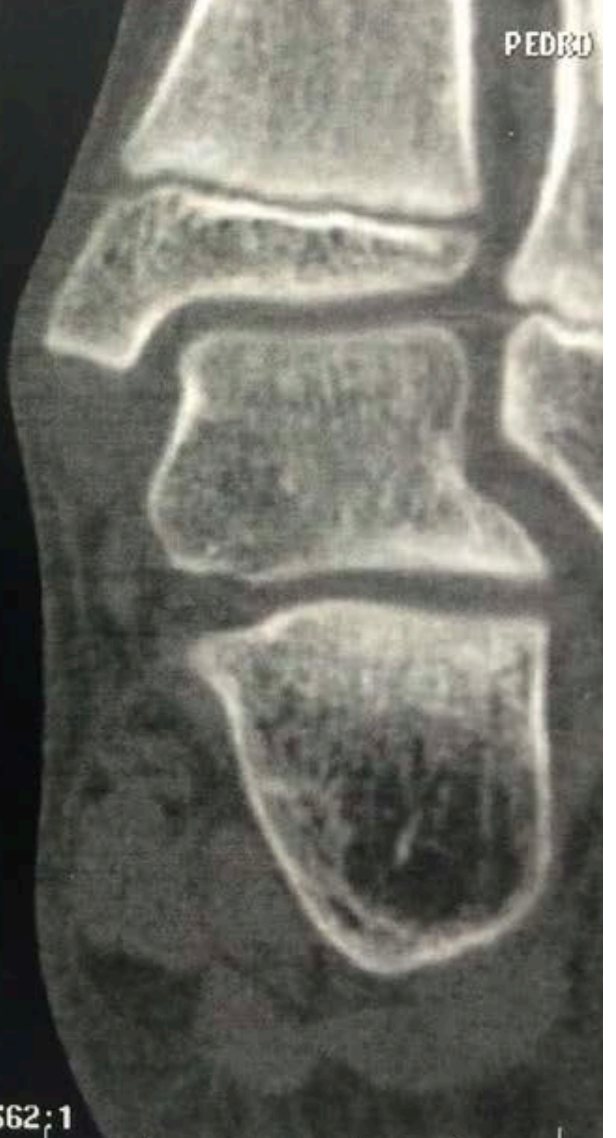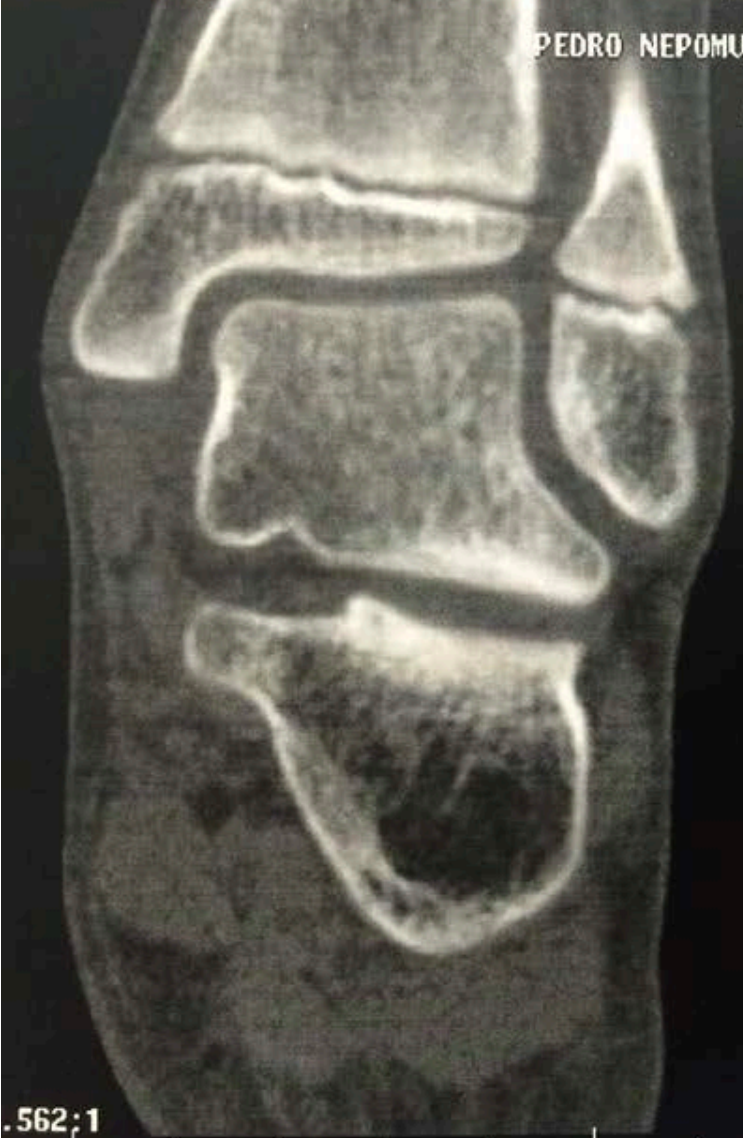Anteater nose sign

16 SYSHctge1 S 23

C.Rad.Campinas H.Vera Cruz
Acc Num:488987
PEDRO NEPOMUCENO DE CARVALHO
M 12 214423
DOB: 04 Feb 2002
10 Dec 2014
512 MF:1.2

LightSpeed Pro 16 SYSHctge1 S 24 C. Ra

Ex: 10748
Se: 300 RFMT
AJ P55.79 0
Im: 27
DFOV 15.1cm
BONE/



L
P
R
A

.562:1

2:17/00.00

I 92

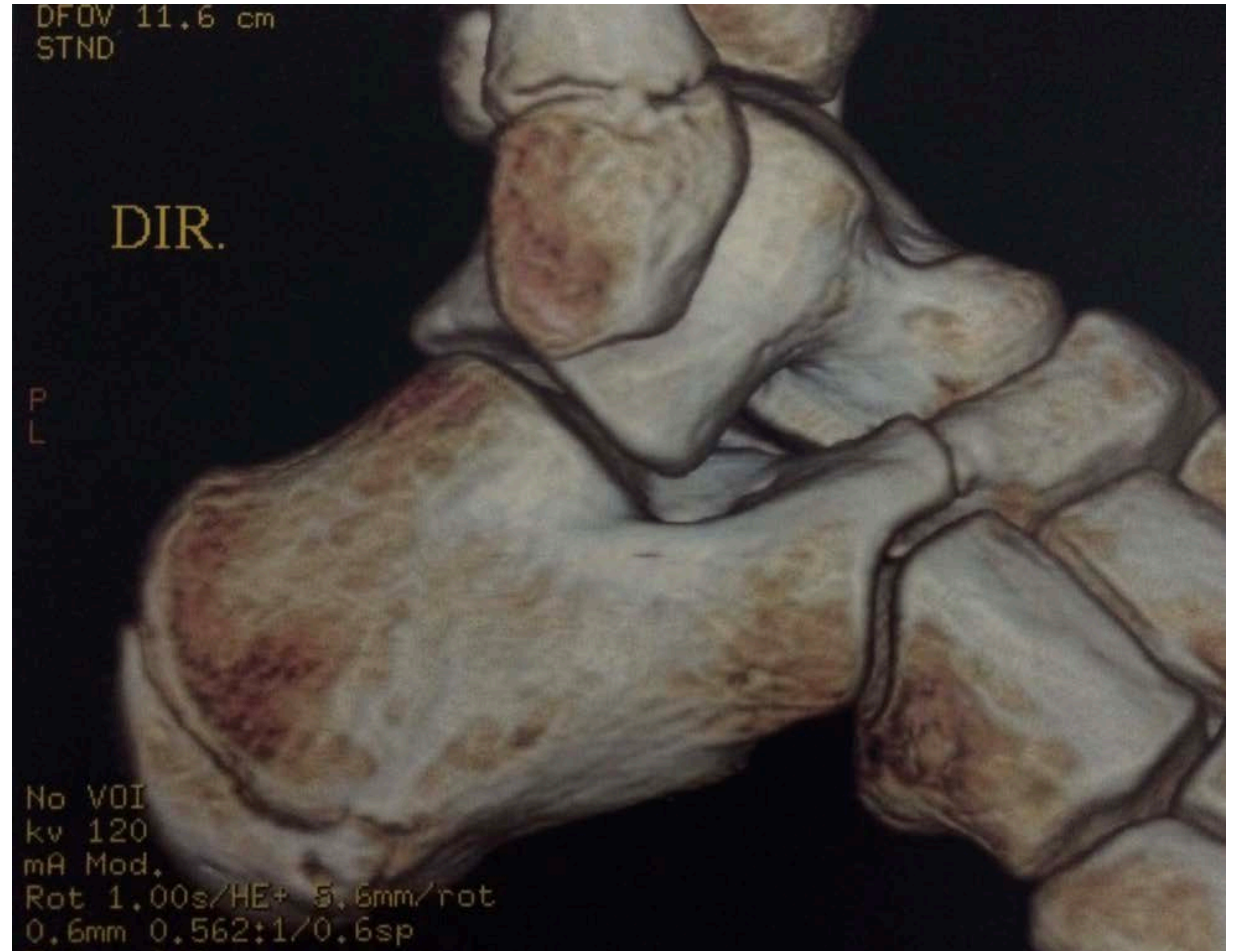
kV 120
mA 89

Large
0.479mm/5.62 0.562:1
Tilt: 0.0
1.0s /HE+ 17:02:17/00.00
W:1435 L:377

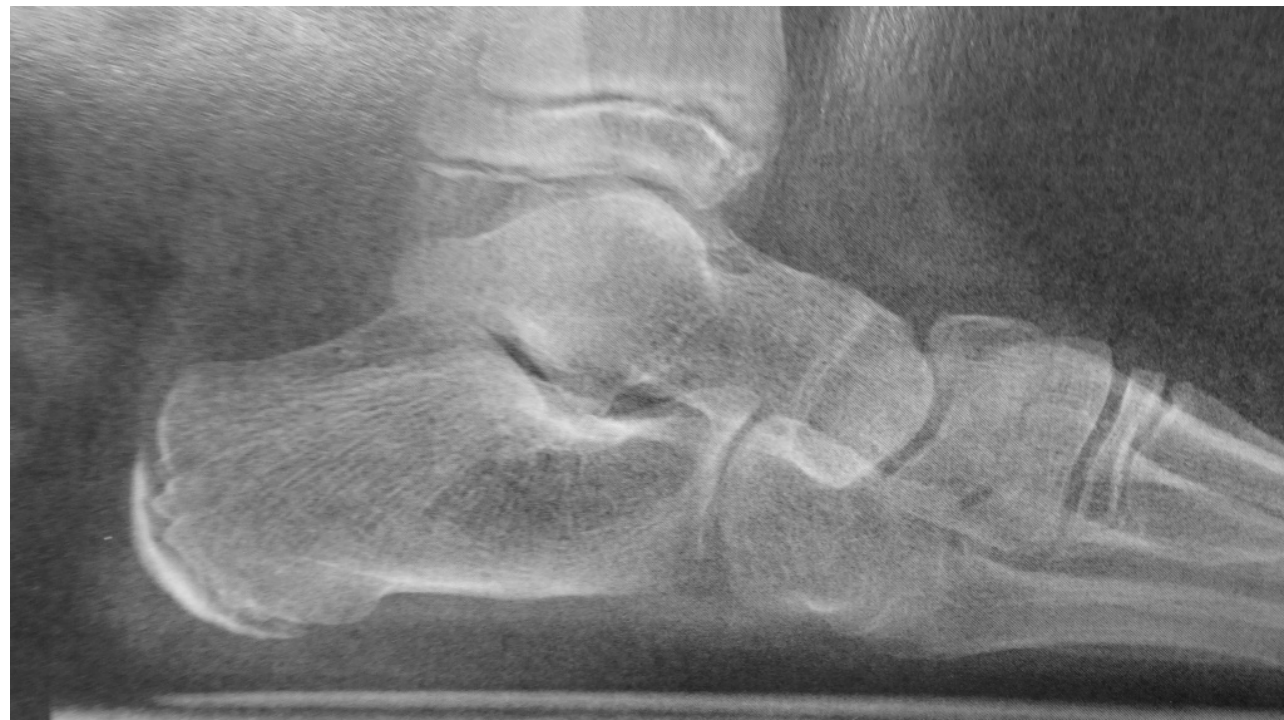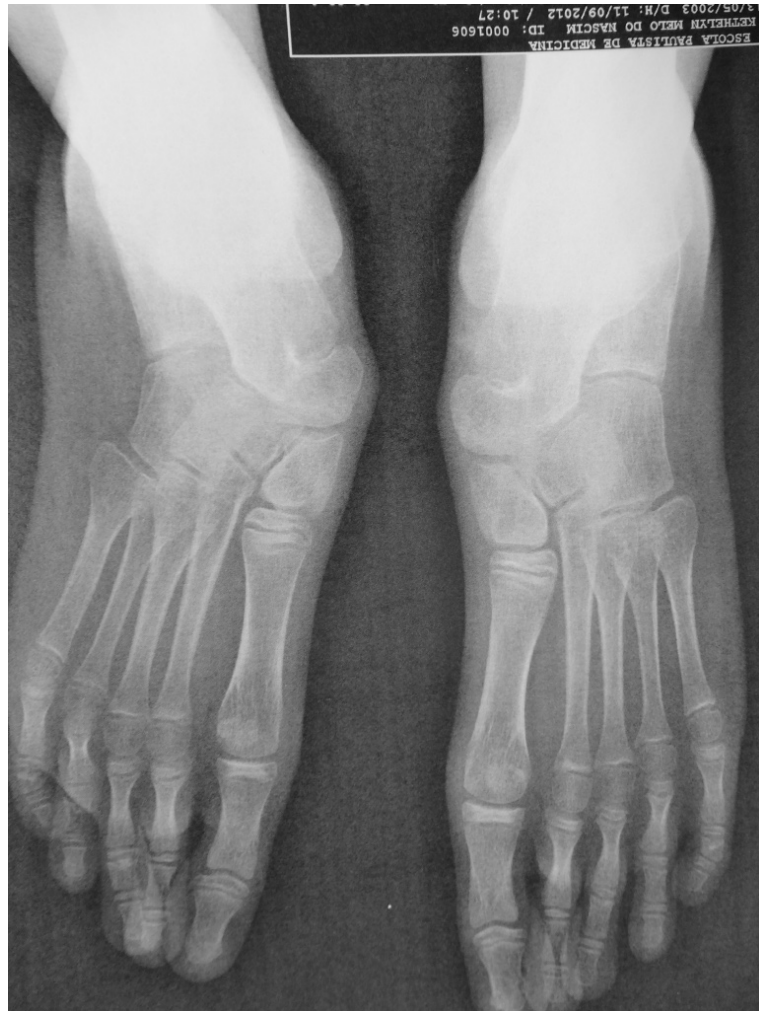I 101

CT scan

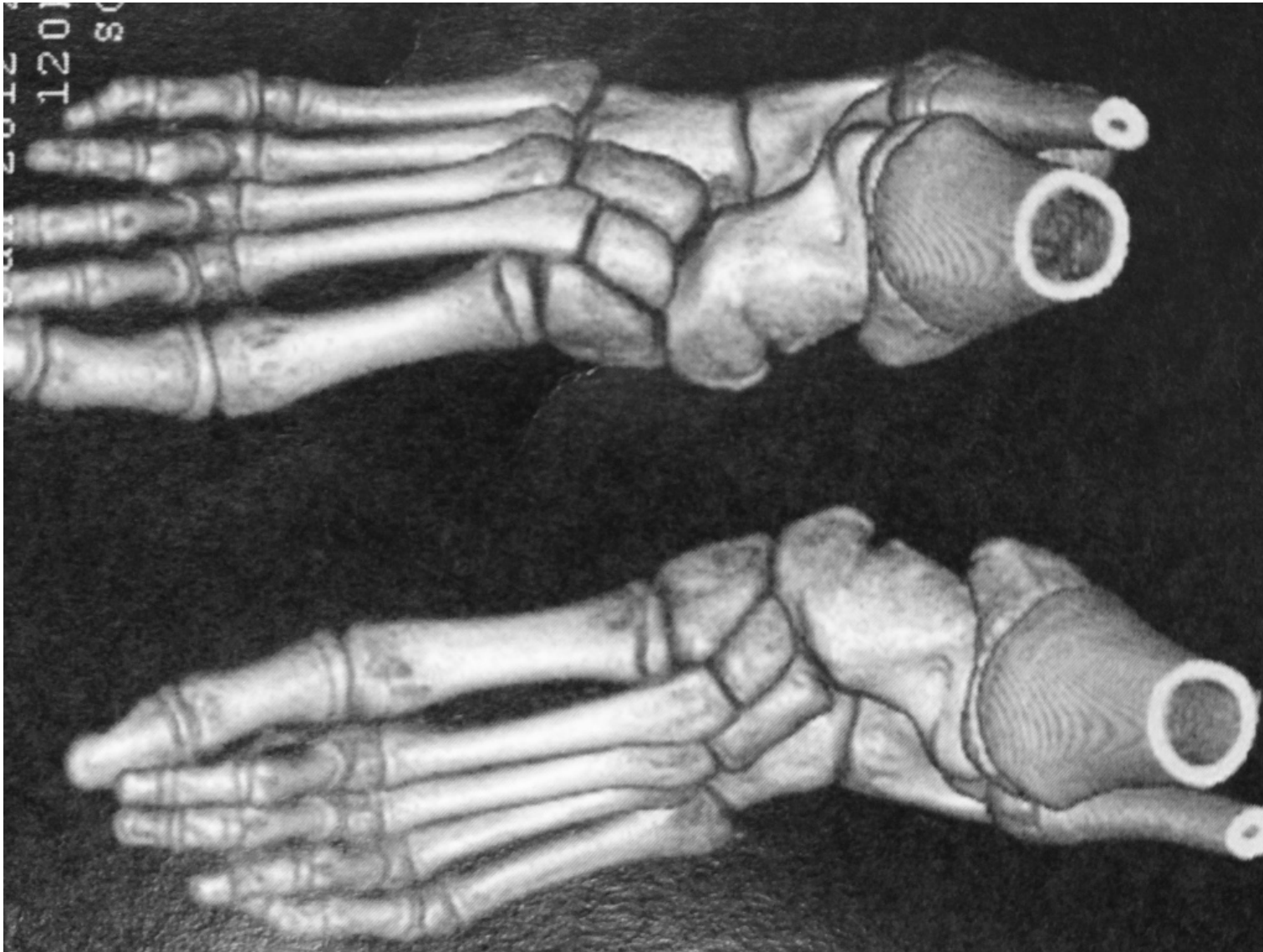
3D CT allows
understanding of
anatomic features and
adjacent tarsal
relationships



Atypical coalitions



CT for atypical coalitions



CT essential for TC coalition

3D CT Reconstructions Invaluable For Detecting, Classifying and Improving The Surgical Treatment Of Talocalcaneal Coalitions

Alison Rozansky, Eric Varley, Molly Moor, Dennis Wenger, & Scott Mubarak

JCOR, 2010

Types of TC coalition

54 feet

Mubarak et al, 2010

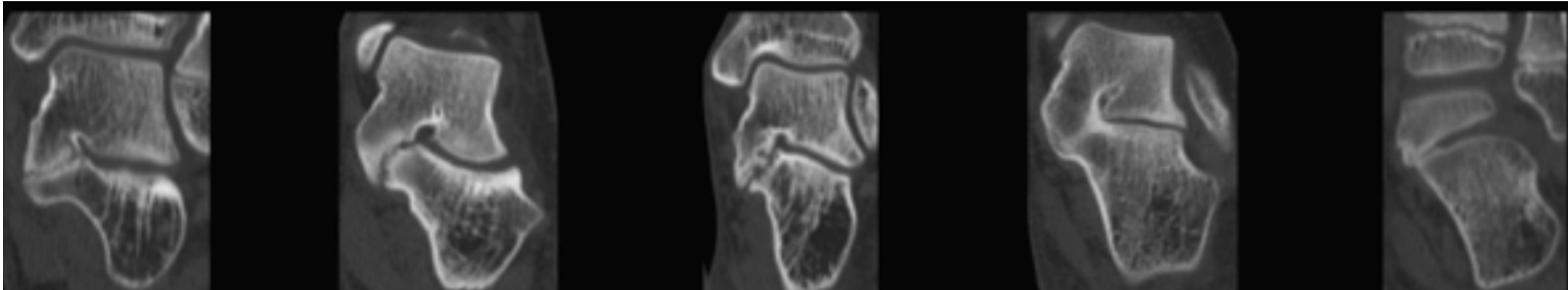
TYPE 1
Linear

TYPE 2
Linear w/posterior hook

TYPE 3
Shingled

TYPE 4
Complete Osseous

TYPE 5
Posterior



41%

17%

14%

11%

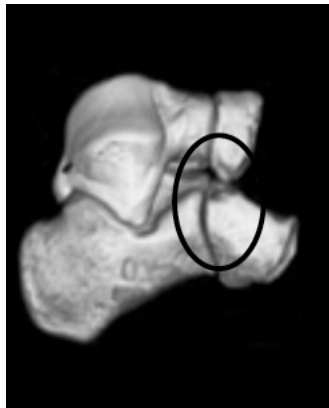17%

Types of CN coalition

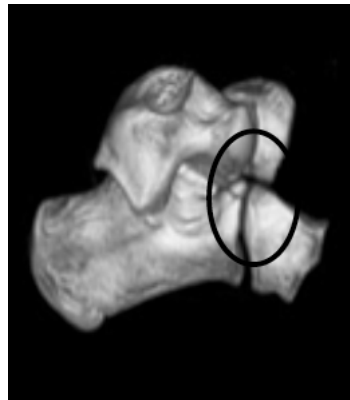
69 feet

Mubarak et al, 2008

Normal

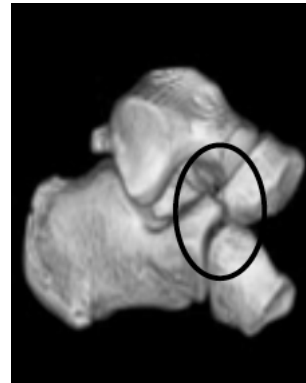

TYPE 1
Forme Frustre



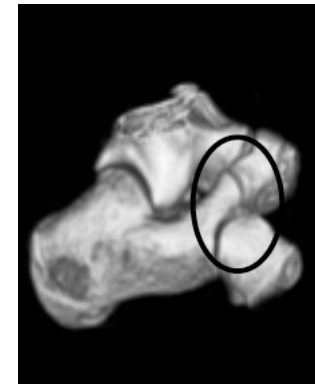28%

TYPE 3
Fibrous



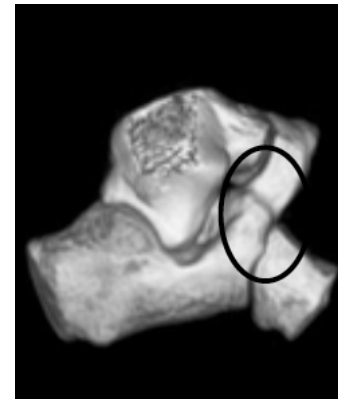23%

TYPE 4
Cartilaginous



45%

TYPE 4
Osseous



4%

Treatment

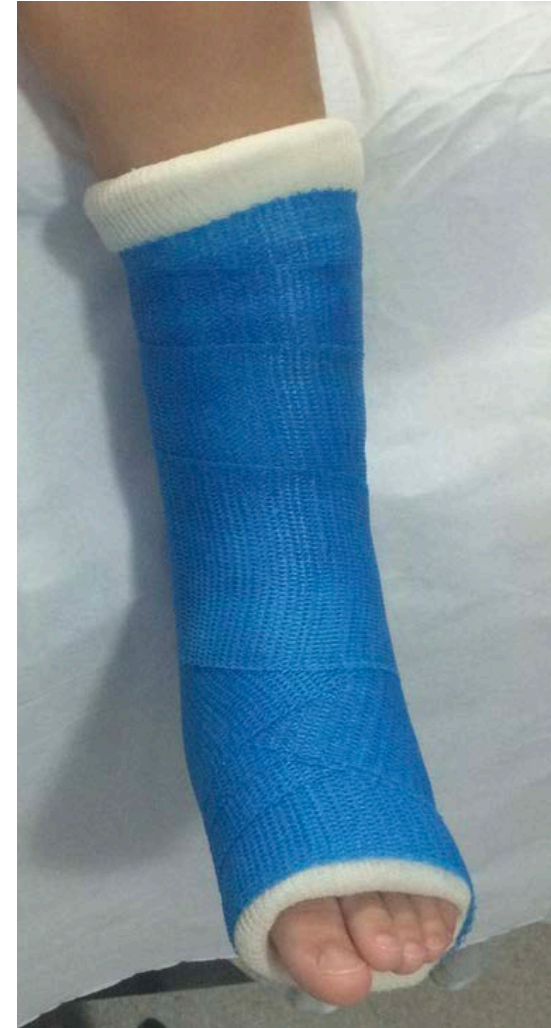- Conservative
 - Cast
 - Insoles - UCBL
- Surgery
 - Resection
 - Osteotomies
 - Arthrodesis

Conservative treatment

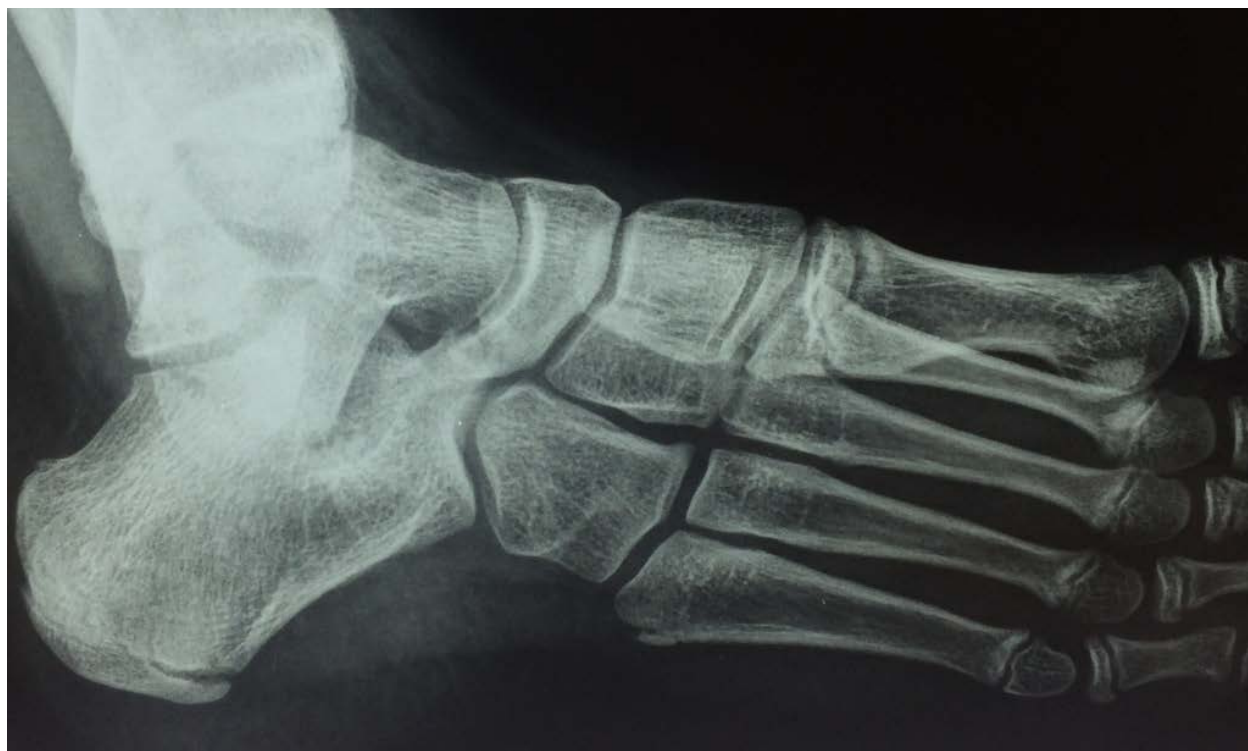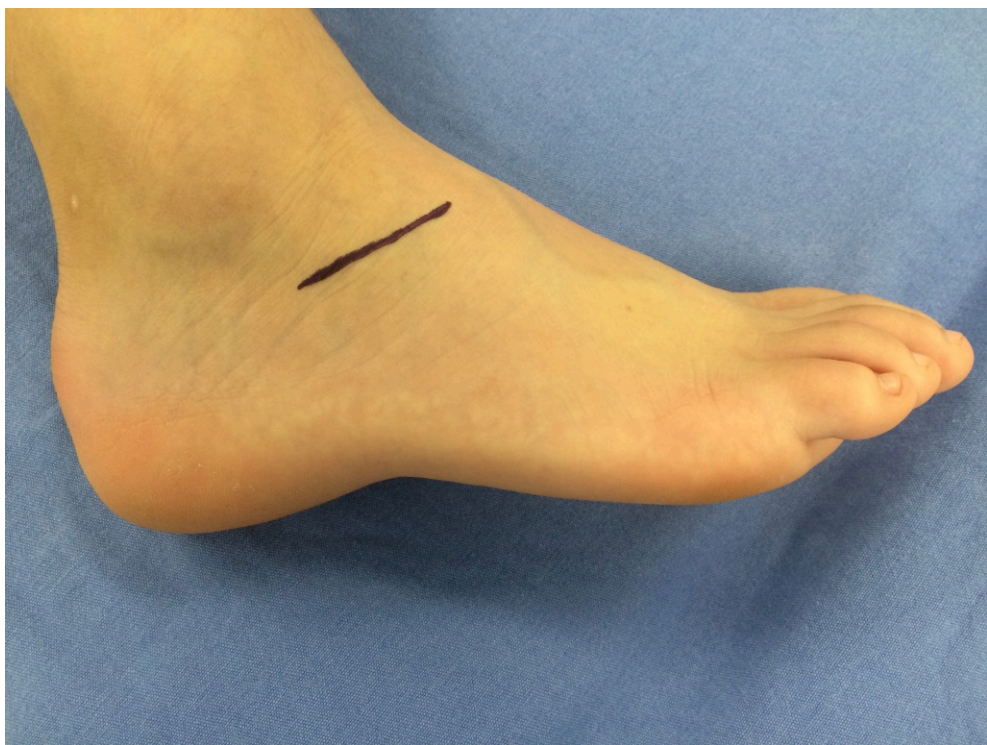- Cast
- Botulinum toxin A?

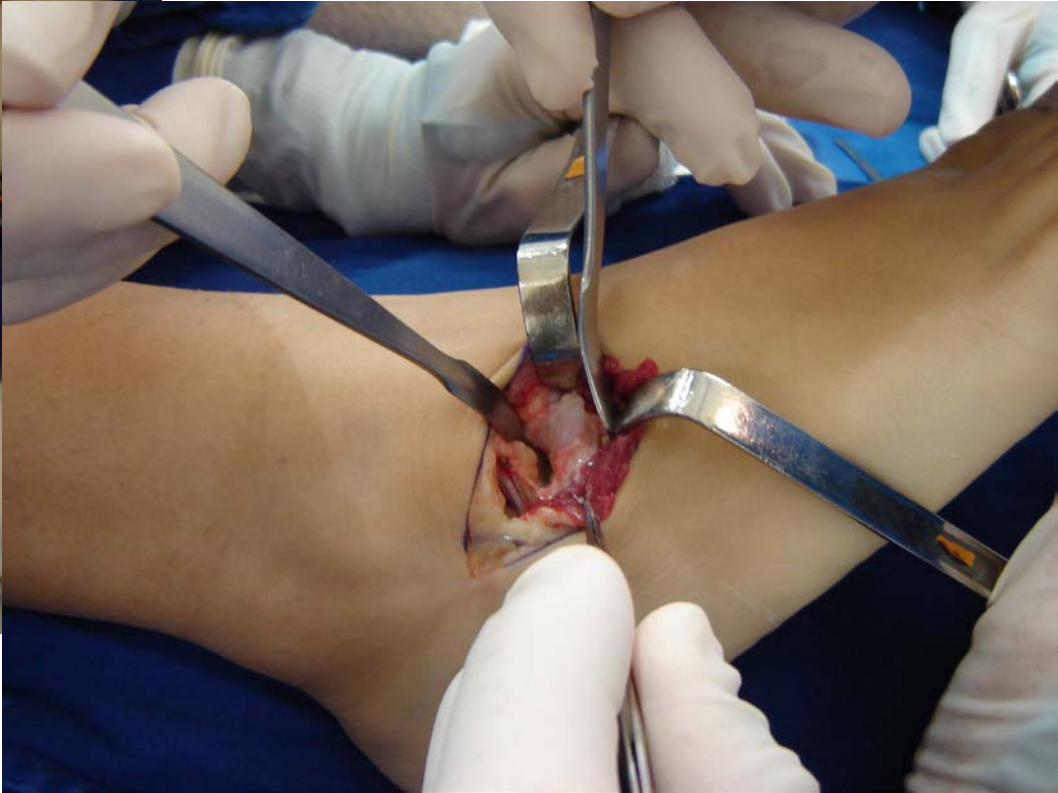
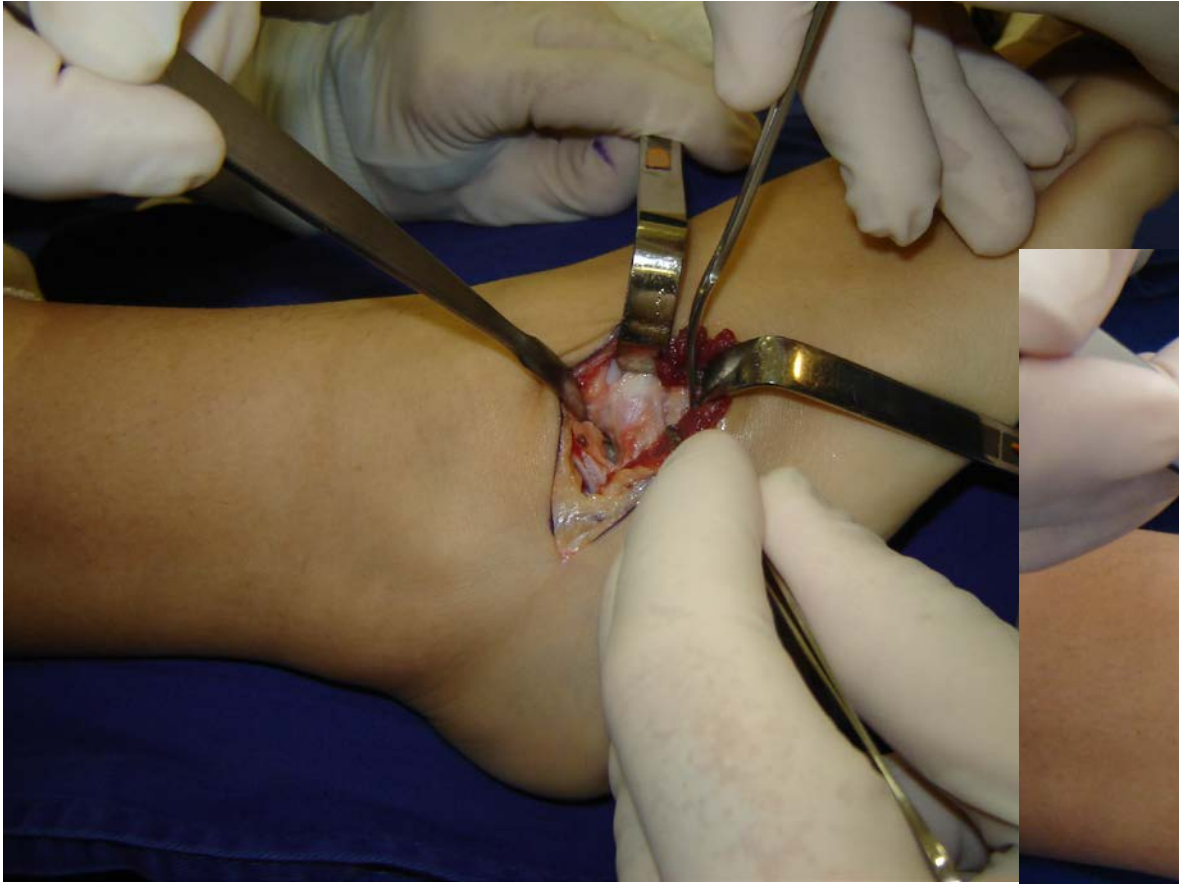
Case Report (without bone coalition)

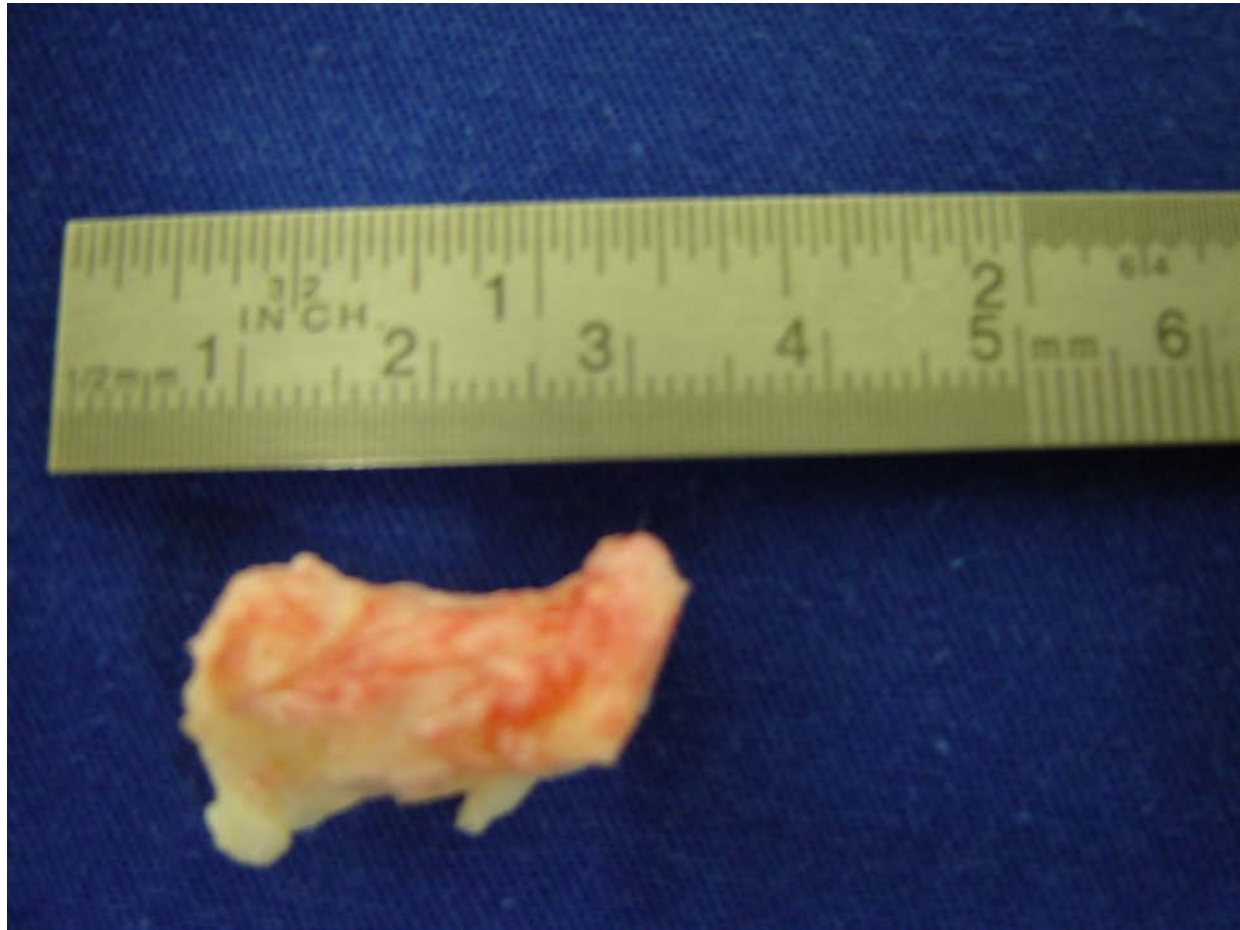
Xu et al *J Foot Ankle Surg*, 2015



CN coalition resection

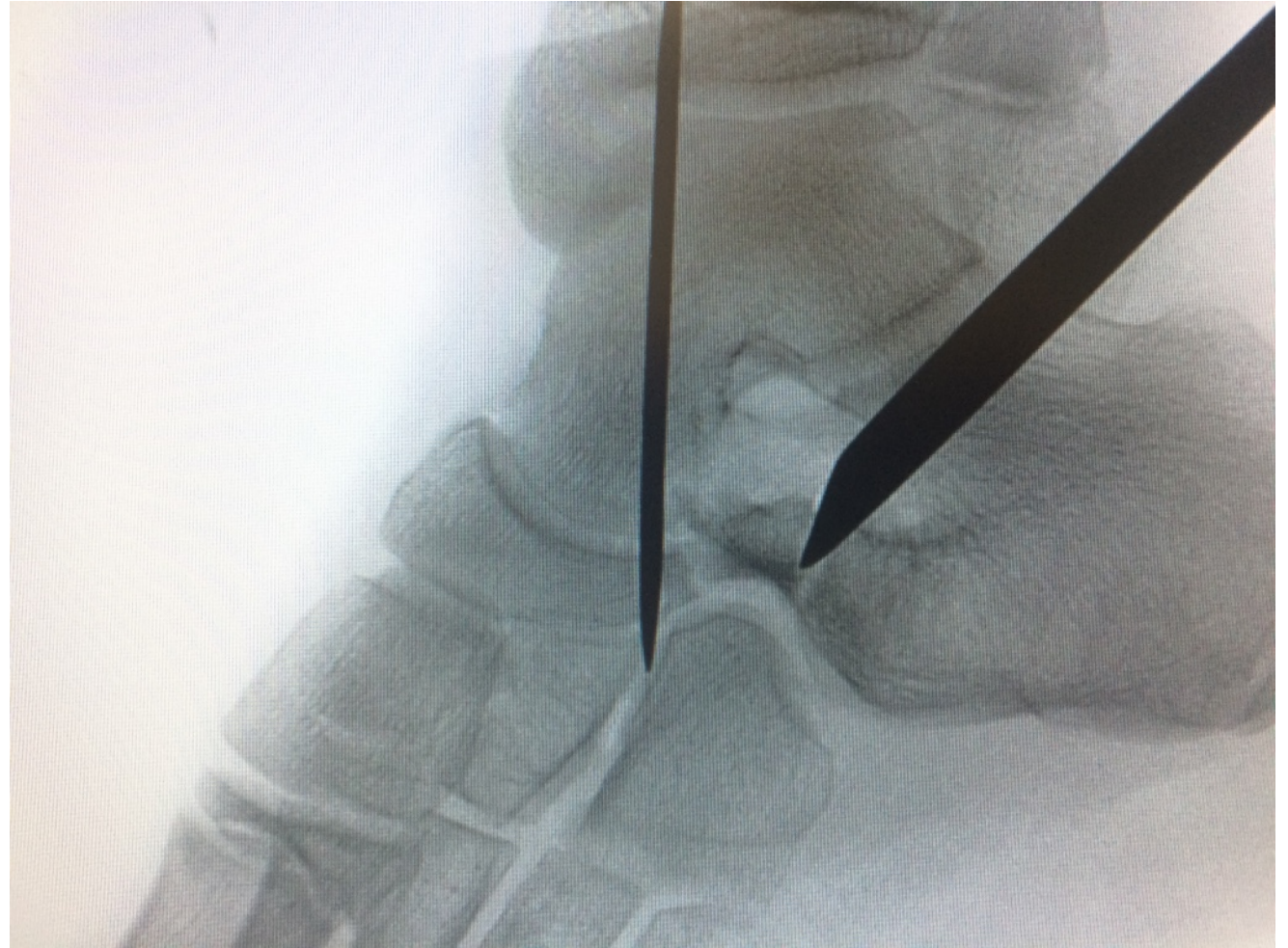



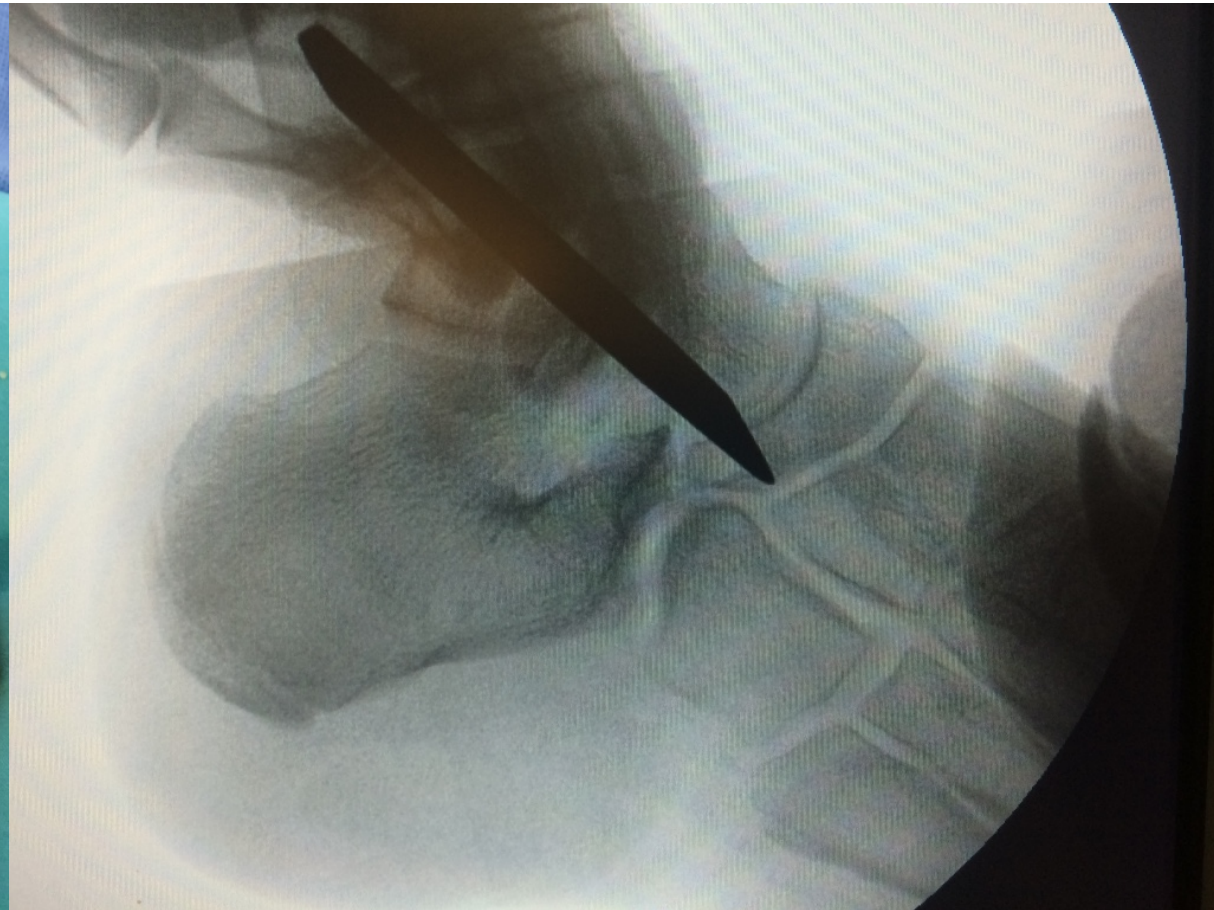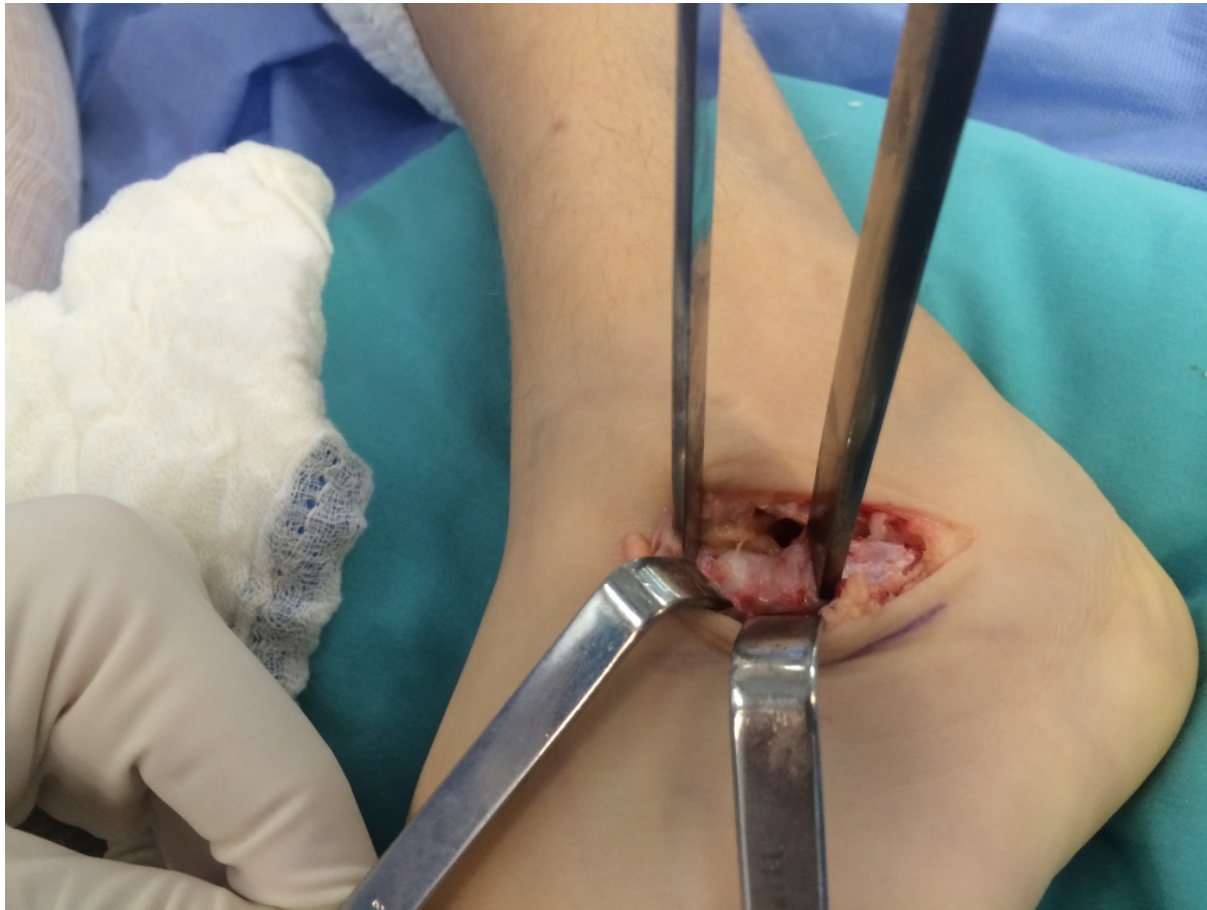


The limits of CN bar resection

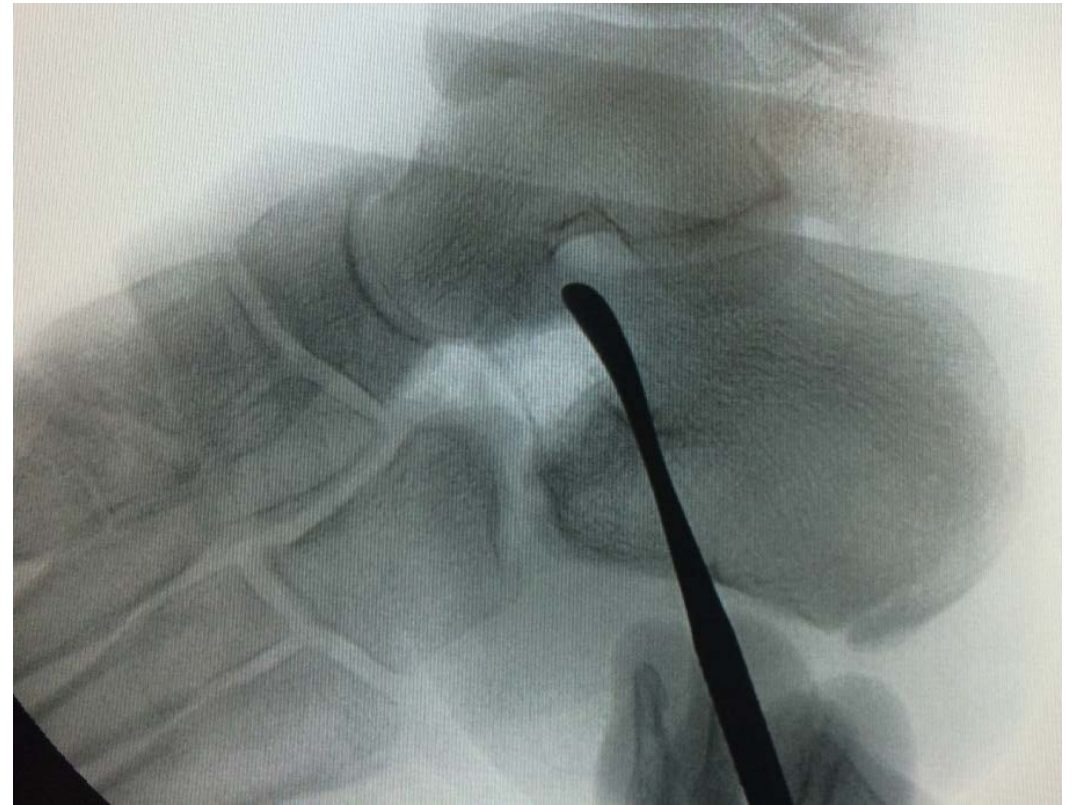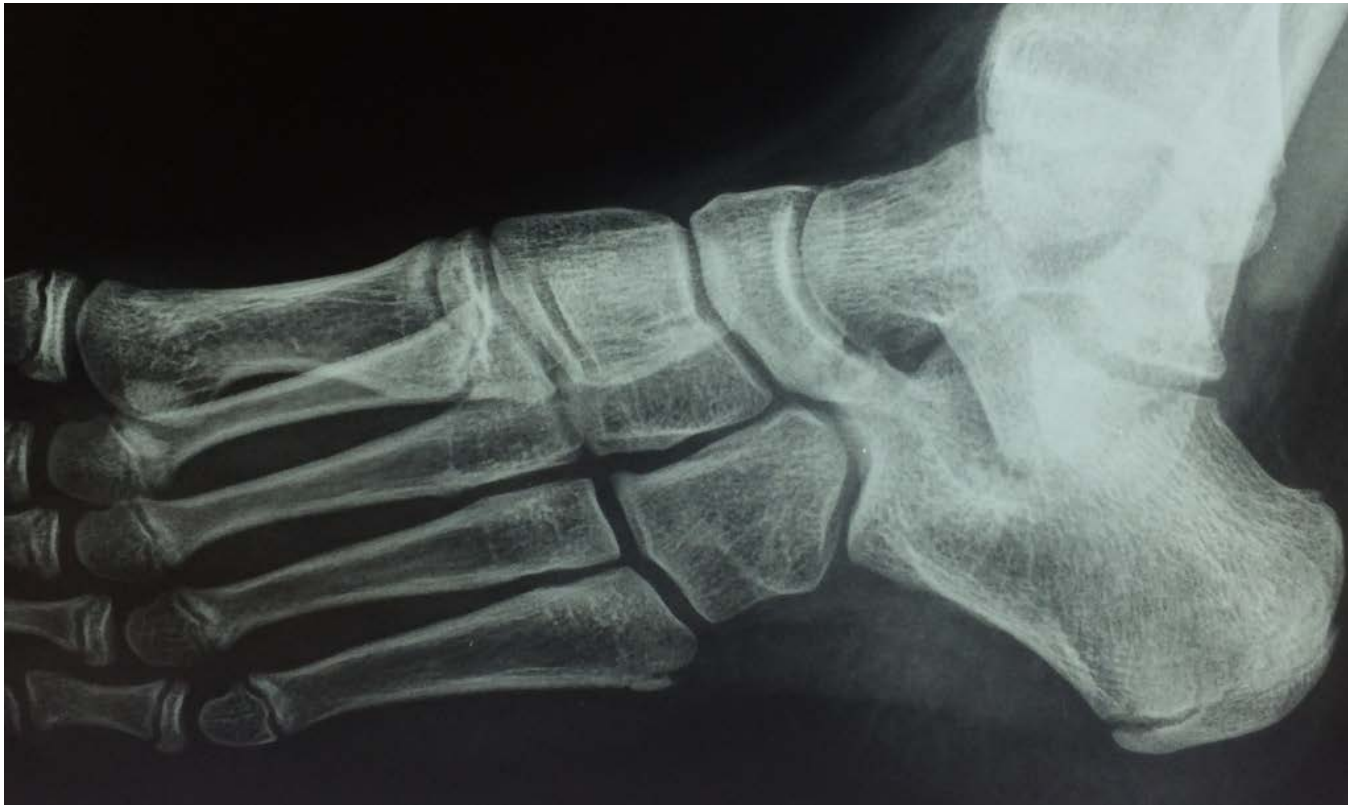- Inferior border talus
- Superior border cuboid



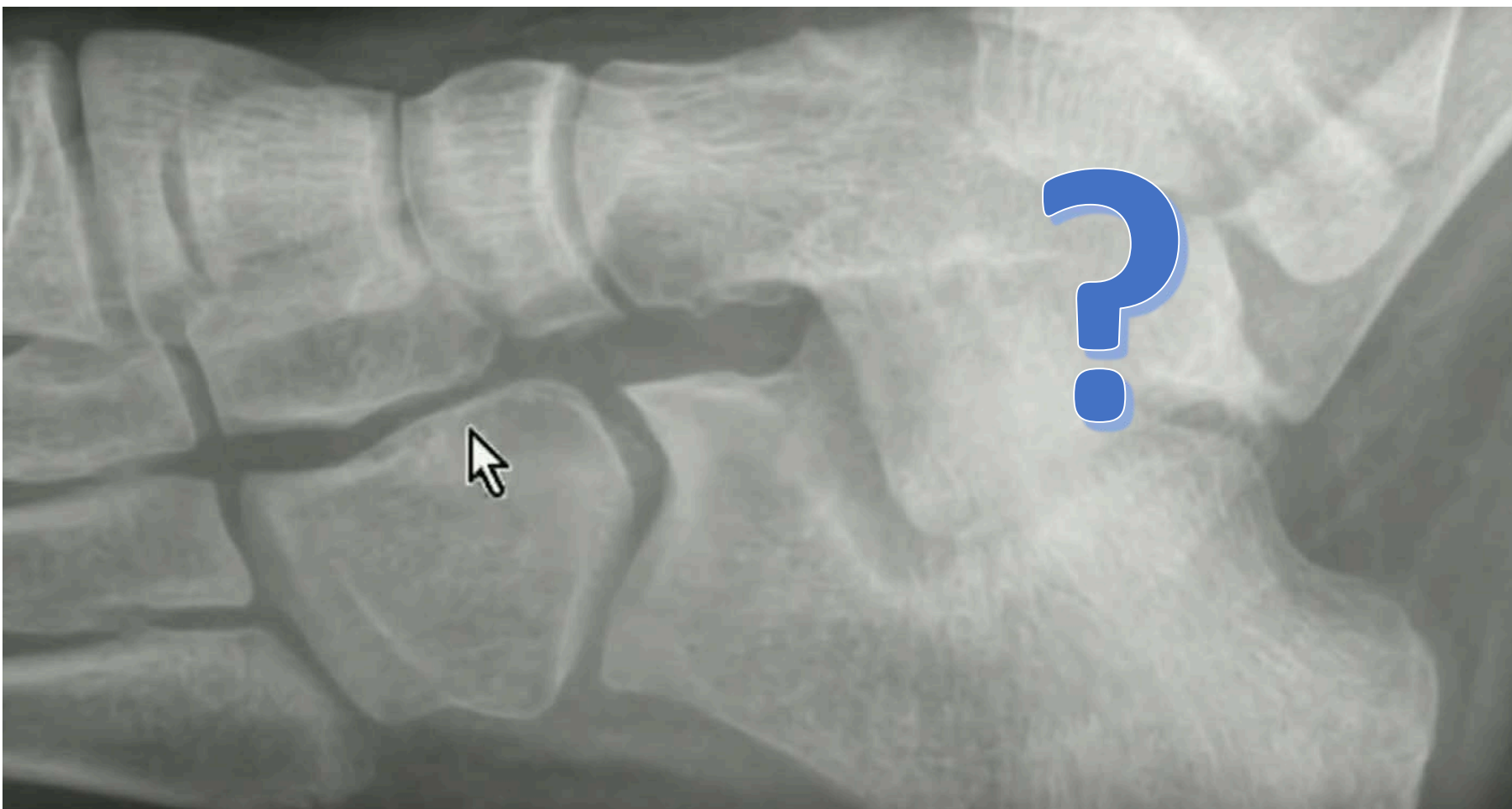
Fluoroscopic control



CN coalition resection



Interposition material

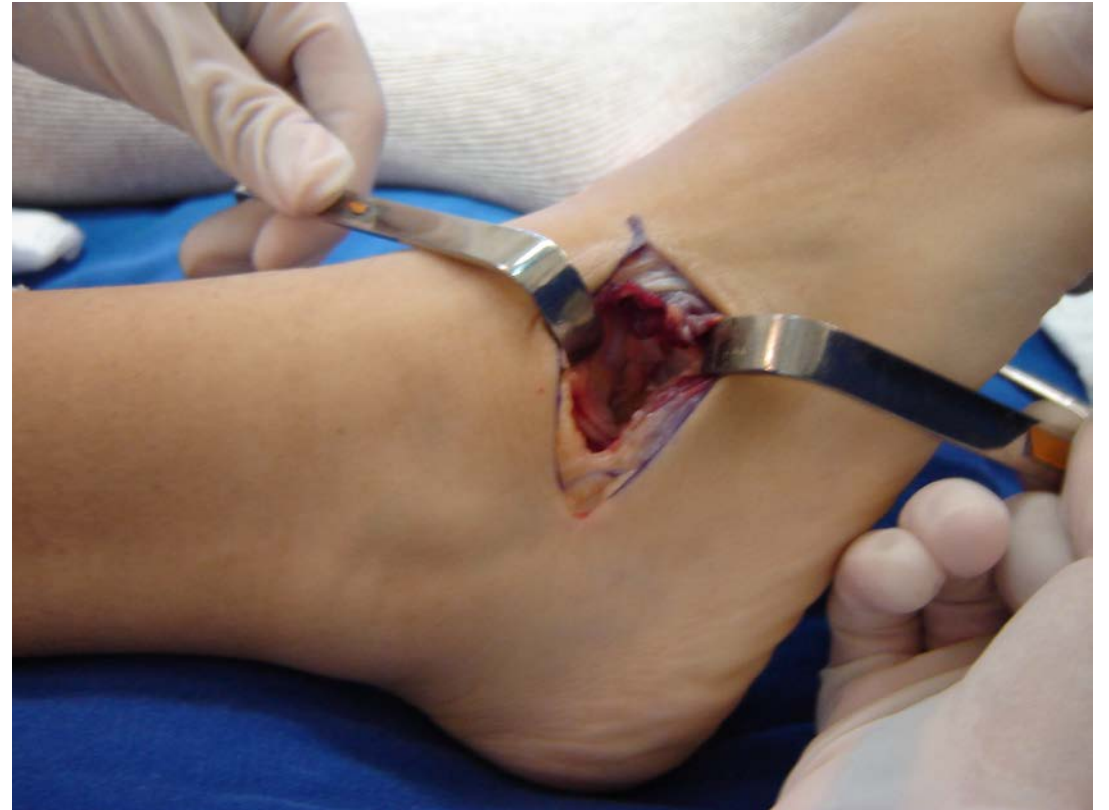
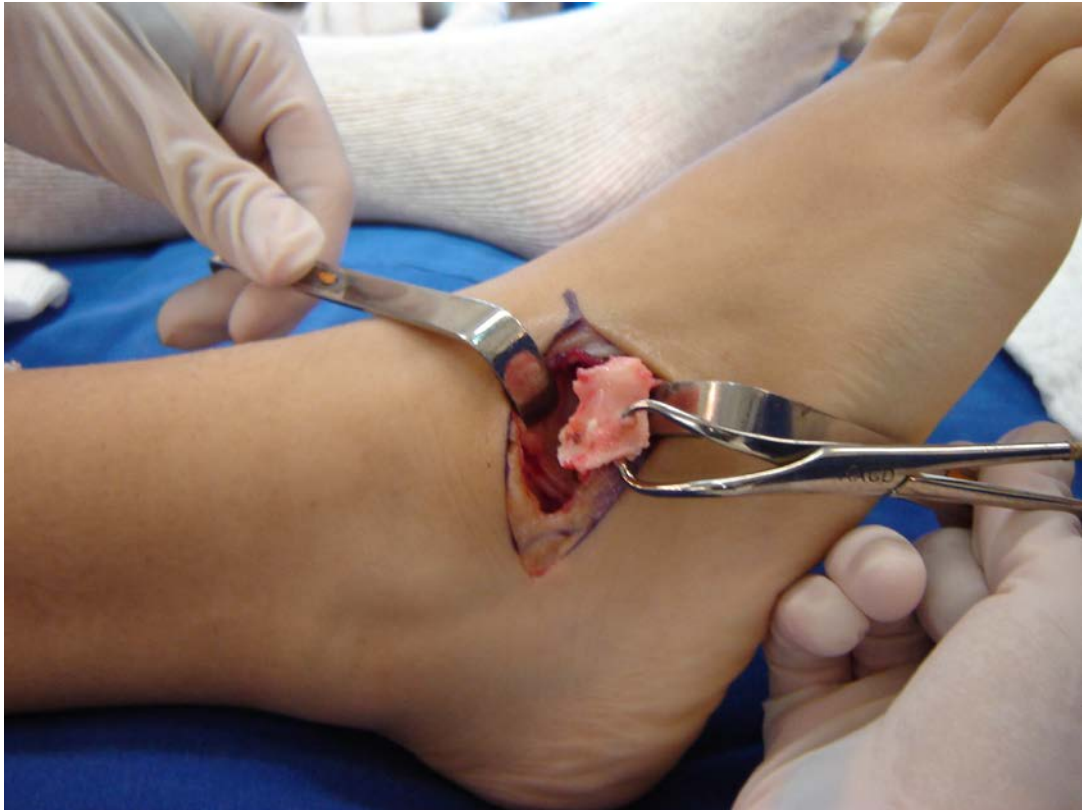
Interposition material

- Extensor brevis
- Fat
- Bone wax
- Juvenile hyaline cartilage graft
- Silicone Sheet

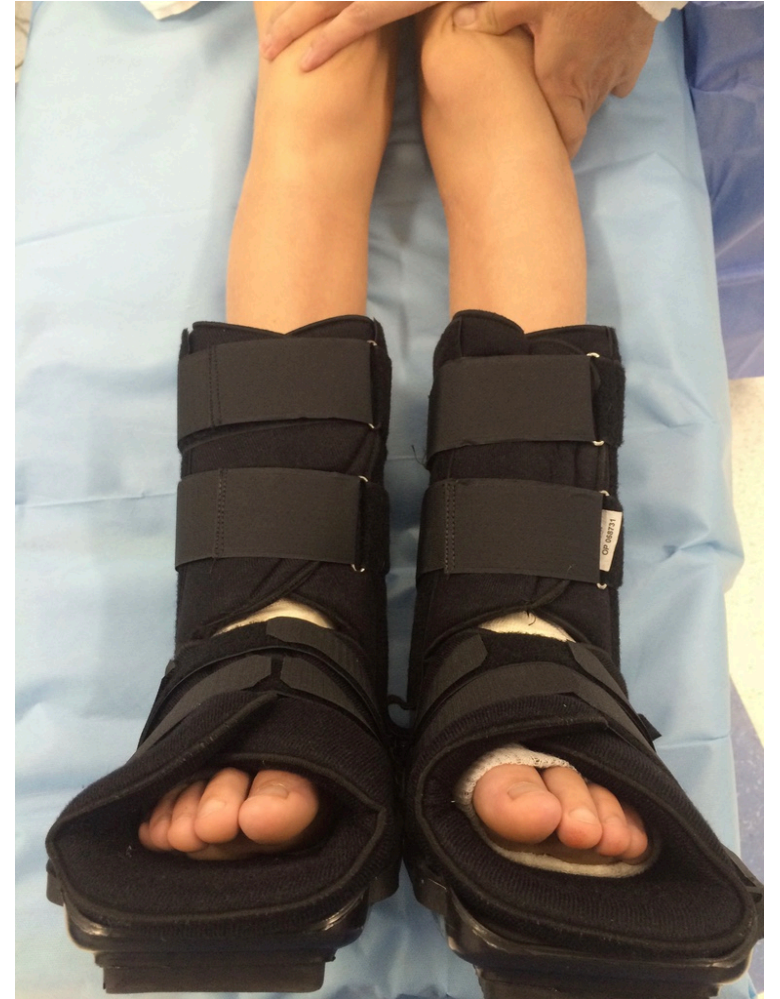Bone wax to bone surfaces

Extensor brevis



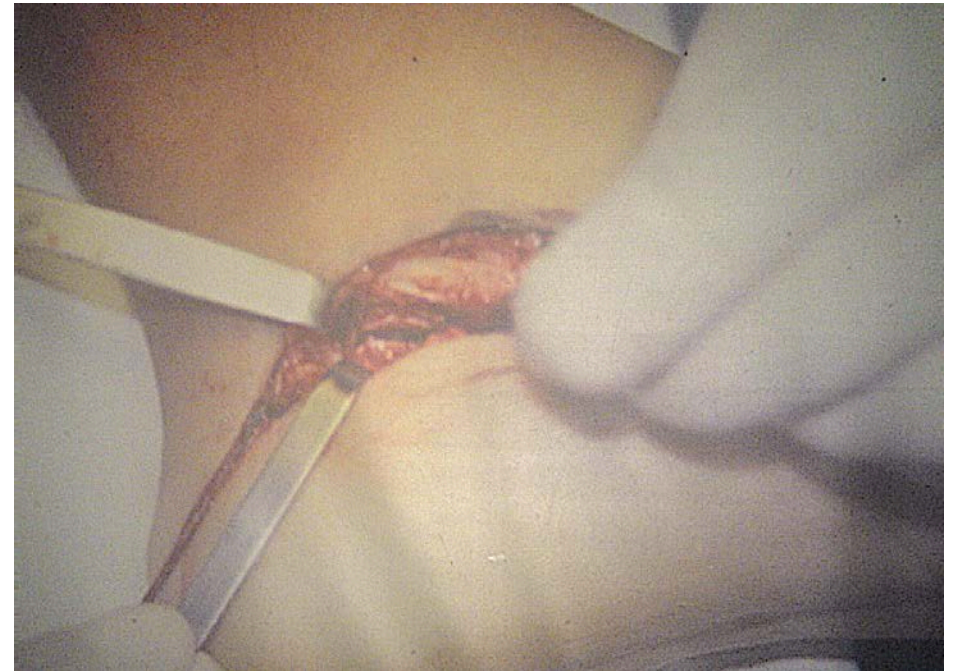
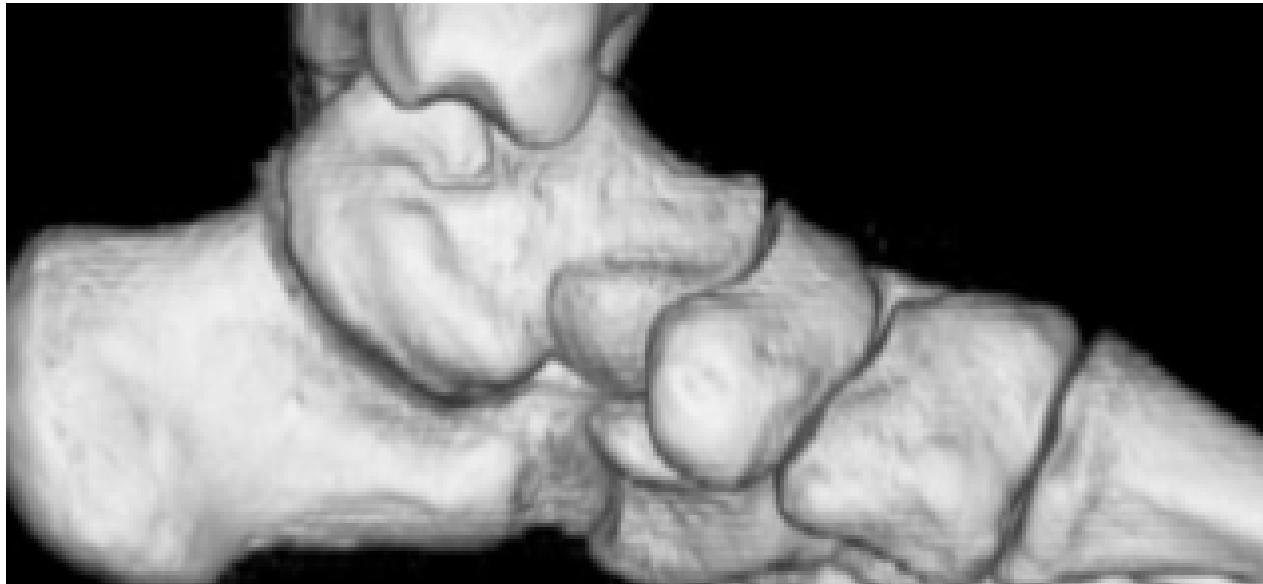
Post-operative

- Boots for 2 weeks
- Walking/standing as tolerated



TC coalition

- Little improvement in motion
- Pain relief (temporary?)



Tarsal coalition + pes valgus

Mubarak

- Resection
- Consider pes valgus correction >6months
- Triple C osteotomy

Talocalcaneal tarsal coalitions and the calcaneal lengthening osteotomy: the role of deformity correction.

Mosca et al, *J Bone Joint Surg Am* 94(17): 1584-94, 2012

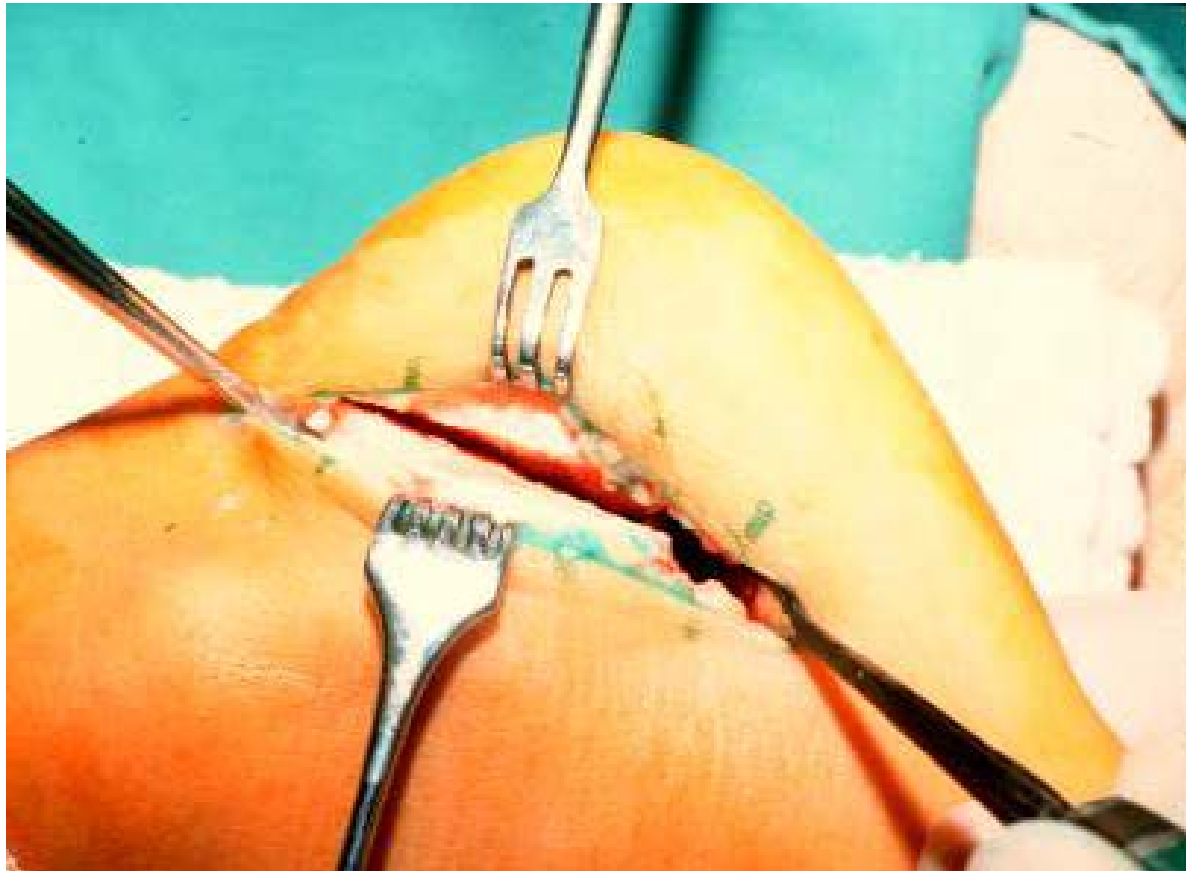8 patients- 13 feet TC coalition

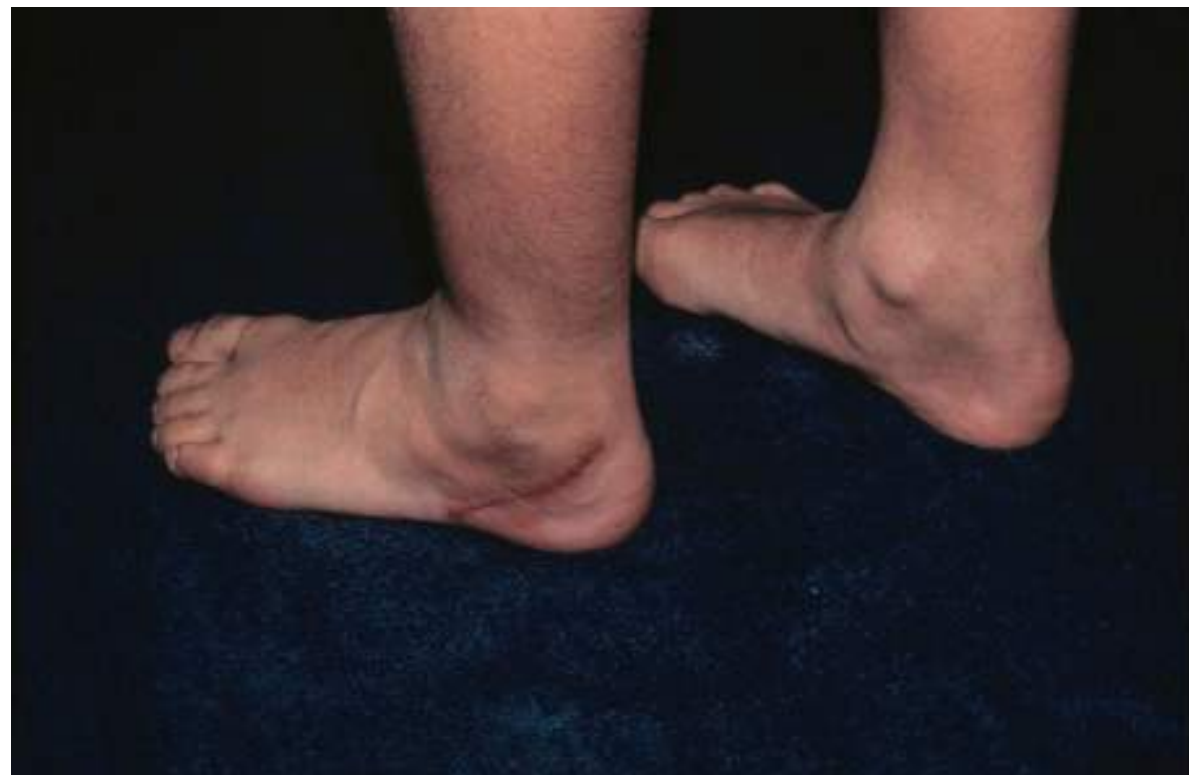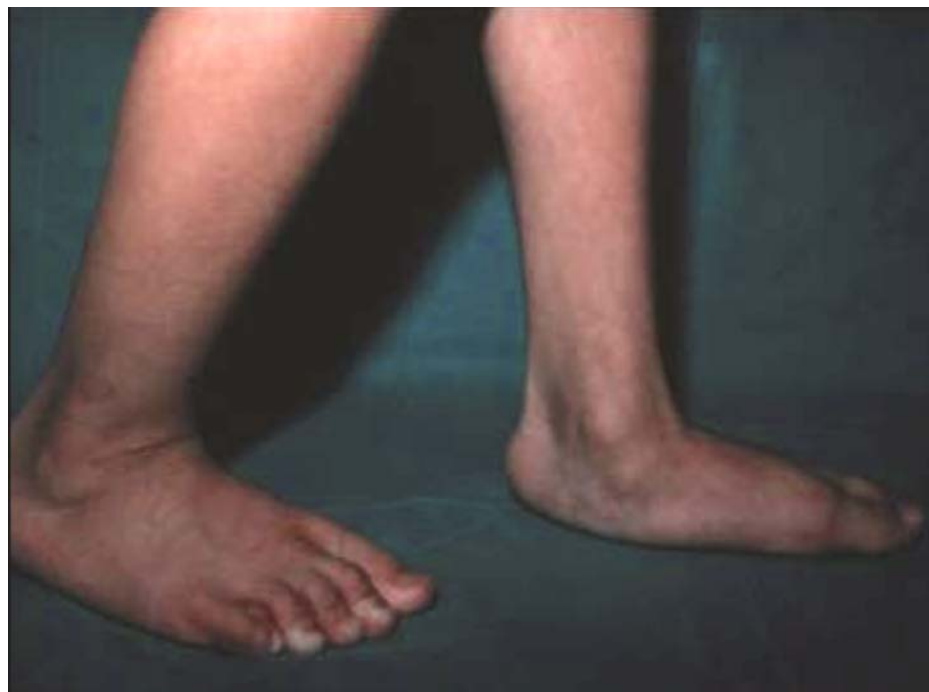1991-2005

Calcaneal lengthening with or w/o resection

My choice: sliding osteotomy or triple C

Leave the TC coalition: realign the foot





Summary

- CN coalition resection usually provides motion and pain relief
- TC coalition: may relieve pain but not motion despite the type of coalition

Summary

- Lack of prospective studies to establish the best treatment for TC coalition
- Realignment of the foot is as important as coalition resection